

Endometriosis results from the dislocation of basal endometrium

G.Leyendecker^{1,3}, M.Herbertz¹, G.Kunz¹ and G.Mall²

Departments of ¹Obstetrics and Gynaecology and ²Pathology, Klinikum Darmstadt, Academic Teaching Hospital to the Universities of Frankfurt and Heidelberg, Grafenstrasse 9, 64283 Darmstadt, Germany

³To whom correspondence should be addressed. E-mail: gerhard.leyendecker@t-online.de

BACKGROUND: The hypothesis is tested that both adenomyotic and endometriotic lesions are derived from basal endometrium. **METHODS:** Normal uteri and uteri with adenomyosis obtained by hysterectomy, excised endometriotic lesions and menstrual blood of women with and without endometriosis were used. Estrogen receptor (ER), progesterone receptor (PR), progesterone receptor B isoform (PR_B) and P450 aromatase (P450A) immunohistochemistry was performed with the use of specific monoclonal antibodies. **RESULTS:** With respect to the parameters studied there was a fundamental difference between the cyclical patterns of the basalis and the functionalis of the eutopic endometrium. The endometrium of endometriotic and adenomyotic lesions mimicked the cyclical pattern of the basalis. The peristromal muscular tissue of endometriotic and adenomyotic lesions displayed the same cyclical pattern of ER and PR expression as the archimyometrium. There was a significantly higher prevalence of fragments of shed basalis in menstrual blood of women with endometriosis than in healthy controls. **CONCLUSIONS:** These data suggest that ectopic endometrial lesions result from dislocation of basal endometrium. Dislocated basal endometrium has stem cell character resulting in the ectopic formation of all archimetrial components such as epithelial and stromal endometrium as well as peristromal muscular tissue.

Key words: adenomyosis/basal endometrium/endometriosis/stem cell potential/uterine hyperperistalsis

Introduction

The development of endometriosis due to the menstrual dissemination of endometrial tissue into the peritoneal cavity (Sampson, 1927) is the theory most widely accepted. It has been corroborated by the finding that endometrial fragments are found in the pouch of Douglas (Bartosik *et al.*, 1986; Kruitwagen *et al.*, 1991a), grow in culture and implant under various experimental conditions (Kruitwagen *et al.*, 1991b; D'Hooghe *et al.*, 1995; Sillem *et al.*, 1996; Koks *et al.*, 1997, 1999; Witz *et al.*, 1999; Maas *et al.*, 2001). Recently, it was shown that eutopic endometrium shares alterations with the ectopic tissue that are not found in the eutopic endometrium of disease-free women. Therefore, the view has been advanced that the primary defect in endometriosis may be located in the eutopic endometrium of these women (Wingfield *et al.*, 1995; Noble *et al.*, 1996, 1997; Jolicoeur *et al.*, 1998; Dmowski *et al.*, 2001).

On the basis of own studies we had suggested that endometriosis and adenomyosis are variants of the same disease process with uterine peristalsis and hyperperistalsis being important causal factors. It was proposed that adenomyosis would result from the infiltration of basal endometrium into myometrial dehiscencies that were caused by chronic uterine peristalsis and hyperperistalsis and that the muscular component of adenomyosis would result secondarily from metaplasia

of the infiltrating endometrial stroma (Kunz *et al.*, 2000a). It was furthermore suggested that endometriosis would result from the detachment of endometrial cells with a higher potential for proliferation and infiltrative growth and from their enhanced transtubal transport by uterine hyperperistalsis into the peritoneal cavity, where they implant on peritoneal surfaces (Leyendecker *et al.*, 1996, 1998; Leyendecker, 2000).

At the end of the secretory phase and at the time of the onset of menstruation, mitotic, and hence proliferative, activity is only present in the basal layer of the primate endometrium, whereas in all of the functionalis and in the spongiosa, mitotic quiescence prevails (Padykula *et al.*, 1989; Okulicz *et al.*, 1993). Furthermore, peristromal smooth muscle cells have been shown to be present in peritoneal endometriotic lesions and they may result from stromal metaplasia of the shed and implanted endometrium (Anaf *et al.*, 2000) indicating that, with respect to the main morphological components, i.e. endometrial epithelium, endometrial stroma and smooth muscular tissue, no principal difference exists between endometriosis and adenomyosis. The production of smooth muscle cells by stromal metaplasia, however, constitutes, during organogenesis and in the adult, a potential that is confined to the basal endometrium at the endometrial–myometrial junction (Werth and Grusdew, 1898; Konishi *et al.*, 1984; Fujii *et al.*, 1989). In view of these considerations we tested the hypothesis

that both adenomyosis and endometriosis result from the dislocation of basal endometrium: adenomyosis by direct infiltration of basalis into the myometrial wall and endometriosis following the detachment of fragments of the basalis during menstruation and their transplantation into the peritoneal cavity.

Materials and methods

Tissue and menstrual blood samples

Tissue samples

Non-pregnant uteri were obtained from 70 pre-menopausal women (aged 24–55 years) undergoing hysterectomy for various reasons. Of these women, 51 were suffering from endometriosis and/or adenomyosis (aged 26–55, mean 42 years). The uteri of the remaining 19 women (aged 24–49, mean 36 years) were devoid of endometrial and myometrial pathology and during laparotomy of these women there were no signs of endometriosis. All women had regular cycles and no history of hormone therapy for ≥ 6 months. The respective phases of the cycle were defined by correlating the date of the last menstrual period with histological findings according to the usual histological dating method (Dallenbach-Hellweg and Poulsen, 1984).

In addition, a total number of 35 classical type (Nisolle *et al.*, 1990; Brosens *et al.*, 1994) endometriotic lesions were obtained via laparoscopy or laparotomy from normally cycling pre-menopausal women (aged 25–51, mean 35 years) without hormone therapy for at ≥ 6 months. These specimens were excised from various intra- and extraperitoneal locations such as the parietal, intestinal, uterine, urinary bladder peritoneum ($n = 25$), the pouch of Douglas with extension into the recto-vaginal septum ($n = 4$) and ovarian endometriomas ($n = 6$) respectively. In all cases the exact phase of cycle was known. The data obtained from individual uterine specimens and endometriotic lesions of the pre-menopausal women were grouped according to phase of the menstrual cycle, with days 1–3 representing the menstrual period (MP), days 4–7 early proliferative (EPP), days 8–11 mid-proliferative (MPP), days 12–14 late proliferative (LPP), days 15–18 early secretory (ESP), days 19–23 mid-secretory (MSP) and days 24–28 late secretory phase (LSP) of the cycle respectively. Detailed information regarding the histological phases of the endometrial cycle in relation to the number of tissue samples used for immunohistochemistry of ER, PR, PR_B and P450 aromatase (P450A) expression is presented in Table I.

The hysterectomy specimens and the excised endometriotic lesions were fixed with 4% buffered formaldehyde (pH 7.1) for 24 h.

Sagittally oriented sections of the uterine corpus in the median line were taken from the fundal region and from the anterior and posterior wall containing the entire uterine wall from the uterine cavity to the serosa. One half of the uterine corpus was cut into at least seven slices starting from the tubal isthmus along the intramural passage of the tube (orthogonally with respect to the endometrial surface) to identify adenomyotic and subserosal endometriotic lesions respectively.

The uterine tissue sections and the excised endometriotic lesions were embedded in paraffin.

Menstrual blood samples

A total number of 43 menstrual blood samples was collected from 19 healthy women (aged 25–37, mean 33 years) and 24 women (aged 24–42, mean 33 years) with endometriosis. All women included in this part of the study had undergone laparoscopy and in cases of endometriosis staging of the disease was performed according to the revised AFS classification of the American Society for Reproductive

Medicine (13, five, three and three patients were stage 1, 2, 3 and 4 respectively). All women had regular cycles and no history of hormone therapy for ≥ 6 months. They came into our Unit in the morning of their second day of menstruation after having used just a sanitary pad during the previous night. In all women ~ 1 ml of menstrual blood was aspirated from the posterior vaginal fornix into a syringe pre-filled with 2 ml of 4% buffered formaldehyde (pH 7.1) for fixation.

Before being embedding in paraffin, the menstrual blood samples were washed with NaCl solution to remove blood cells.

Immunostaining

All immunohistochemical procedures were performed by using an automated slide stainer (Ventana NexES IHC Staining System; Ventana Medical Systems Inc., Tucson, AZ, USA). Paraffin-embedded sections (thickness 3 μ m) were mounted on slides before deparaffination and rehydration.

Estrogen receptor (ER), progesterone receptor (PR) and progesterone receptor B isoform (PR_B)

Unmasking of antigen was carried out by using a microwave. The sections were then transferred to the Ventana NexES IHC Staining System. The following antibodies were used: anti-ER mouse monoclonal antibody developed against the alpha form of the estrogen receptor molecule, at a dilution of 1:10 (Novocastra Laboratories, Newcastle upon Tyne, UK); anti-PR mouse monoclonal antibody developed against both known types of nuclear progesterone receptors (PR_A and PR_B) (Viville *et al.*, 1997) at a dilution of 1:10 (Novocastra Laboratories); anti-PR isoform B mouse monoclonal antibody developed against the PR isoform B (PR_B) at a dilution of 1:5 (Santa Cruz Biotechnology, Inc., USA). In the immunohistochemistry of PR_B an amplification kit (Ventana Medical Systems Inc.) was used for the enhancement of the staining.

Sections of receptor-positive mammary carcinomas served as positive controls. Negative controls were made using sections of receptor-positive mammary carcinomas without incubation with primary antibody and several ER-negative tissues (e.g. from tonsils and non-gynaecological carcinomas) using the same automated procedure.

P450 aromatase (P450A)

The unmasking of the antigen and the following automated staining procedure were the same except for the use of a Basic Alkaline Phosphatase Red Detection Kit. The staining was performed with primary rabbit anti-aromatase cytochrome P450 polyclonal antibody recognizing human placental cytochrome P450A at a dilution of 1:1000 in Ventana antibody diluent (Hauptman–Woodward Medical Research Inst., Inc., Buffalo, NY, USA). Sections of normal ovarian tissue containing Graafian follicles served as positive controls. Several P450A-negative tissues (e.g. from tonsils and non-gynaecological carcinomas) served as negative controls.

Actin

Unmasking of antigen was performed by a protease solution (Ventana Medical Systems, Inc.) followed by the same staining procedure as described for P450A. The primary anti-muscle actin antibody (clone HUC 1-1) was provided by Ventana Medical Systems, Inc. in a pre-diluted manner.

The specific actin immunostaining was used to identify peristromal smooth muscle cells in endometriotic and adenomyotic lesions thereby facilitating the evaluation of their ER and PR staining.

Evaluation

Estrogen receptor, progesterone receptor

Results of specific nuclear staining were evaluated using a semiquantitative method. The immunoreactive score (IRS) was calculated using

Table I. Histological phases of the endometrial cycle in relation to the number of tissue samples used for immunohistochemistry of estrogen receptor (ER) and progesterone receptor (PR) expression (values in roman type), of PR_B expression (values in bold) and P450 aromatase expression (brackets)

Phase of cycle (days)	Uteri of women with endometriosis		Adenomyotic lesions		Endometriotic lesions		Uteri of healthy controls	
	Endometrium	Myometrium	Epithelium/stroma	PMC	Epithelium/stroma	PMC	Endometrium	Myometrium
EPP (4–7)	10 (15)	10	10 (15)	10	8 (9)	8	4 (5)	4
MPP (8–11)	6 (5)	6	6 (5)	6	9 (9)	9	2 (2)	2
LPP (12–14)	5 (8)	4	3 (8)	3	5 (5)	3	2 (1)	2
ESP (15–18)	4 (5)	4	4 (5)	4	3 (3)	3	3 (2)	3
MSP (19–23)	6 (8)	6	6 (8)	6	5 (4)	2	3 (4)	3
LSP (24–28)	6 (6)	5	5 (6)	5	5 (5)	3	3 (5)	3
MP (1–3)	3 (4)	3	3 (4)	3				
Total	40 (51)	38	37 (51)	37	35 (35)	28	17 (19)	17

Endometrium refers to the separate evaluation of both stroma and epithelium of the functionalis and basalis layers respectively. Myometrium refers to the separate evaluation of the stratum vasculare and the archimyometrium (stratum subvasculare).

PMC = peristromal smooth muscular tissue; EPP, MPP and LPP = early, mid- and late proliferative phase; ESP, MSP and LSP = early, mid- and late secretory phase; MP = menstrual phase.

the following equation: $IRS = \sum P_i (i + 1)$, where $i = 1, 2$ or 3 , and P_i is the percentage of stained cells for each intensity, according to a published method (Lessey *et al.*, 1988). The staining intensity was graded as 0 = no, 1 = weak, 2 = moderate and 3 = strong staining respectively.

The following tissues were evaluated separately: the endometrial epithelium and stroma of the functionalis as represented by zone II and of the deep basalis as represented by zone IV (Padykula *et al.*, 1989); epithelium and stroma of endometriotic and adenomyotic lesions; the outer myometrium represented by the stratum vasculare of the neometra; the archimyometrium (stratum subvasculare) (Leyendecker *et al.*, 1998; Noe *et al.*, 1999); the peristromal muscular tissue of endometriotic and adenomyotic lesions. With respect to the uterine tissues ≥ 20 high power fields and with respect to the endometriotic lesions at least five high power fields were selected at random and evaluated. The immunoreactive score of positively stained cells per uterine region was determined by taking the arithmetic mean of the values of all counted high power fields. There was a high reproducibility of the method in that, in a test series, the inter-assay variation over the full range of IRS was never $> 10\%$.

P450A and PR_B

Results of specific staining were obtained using a semiquantitative method based on a 4-point scale: 0 = no, 1 = weak, 2 = moderate and 3 = strong staining respectively, with strong staining being represented by ovarian tissue serving as the positive control. The evaluation of P450A expression was confined to the glandular epithelium of the eutopic and ectopic endometrium. That of PR_B expression included the respective stroma. The same number of high power fields as described above were used.

Thickness of basal endometrium (zone IV)

To determine the thickness of the basal endometrium, additional hysterectomy specimens to those listed in Table I were used. The measurements were based on the width of the ER-positive basal fringe during the mid-, late secretory and menstrual phases of the cycle respectively of patients with endometriosis/adenomyosis ($n = 20$; aged 32–53, mean 41 years) and healthy controls ($n = 7$;

aged 28–45, mean 37 years). The specimens were taken from sagittally oriented sections of the fundal region and of the anterior and posterior uterine wall containing the complete width of the endometrium in a 90° angle with respect to the endometrial surface. A total of 15 measurements per uterus at randomly selected sites was performed. Care was taken that the measurements did not include sites of adenomyotic infiltration. The results of the measurements were expressed as arithmetic means.

Menstrual blood samples

A series of four sequential sections of the endometrial fragments derived from the menstrual blood specimen were examined for the presence or absence of fragments that stained for ER, PR, PR_B and P450A expression respectively. The evaluation of the individual menstrual blood specimen in this respect was based on the examination of only one section for each of the above parameters.

Statistical analysis

Statistical analysis was performed with Student's *t*-test for unpaired data and Fisher's test. $P < 0.05$ was considered significant.

Results

Immunohistochemistry of ER, PR and PR_B and of the P450A respectively showed positive staining in all layers of the endometrium during the proliferative phase of the cycle. During the secretory phase of the cycle the immunostaining of ER, PR and P450A progressively decreased and became nearly negative in the late secretory phase in the functionalis including the spongiosa while remaining positive in the basalis layer. Immunostaining for PR_B isoform became negative in all endometrial layers at the end of the cycle. With respect to these patterns there was no difference between women with endometriosis and/or adenomyosis and those without the disease. The immunohistochemically positive fringe at the end of the secretory phase had a width of 0.4 ± 0.08 mm (mean

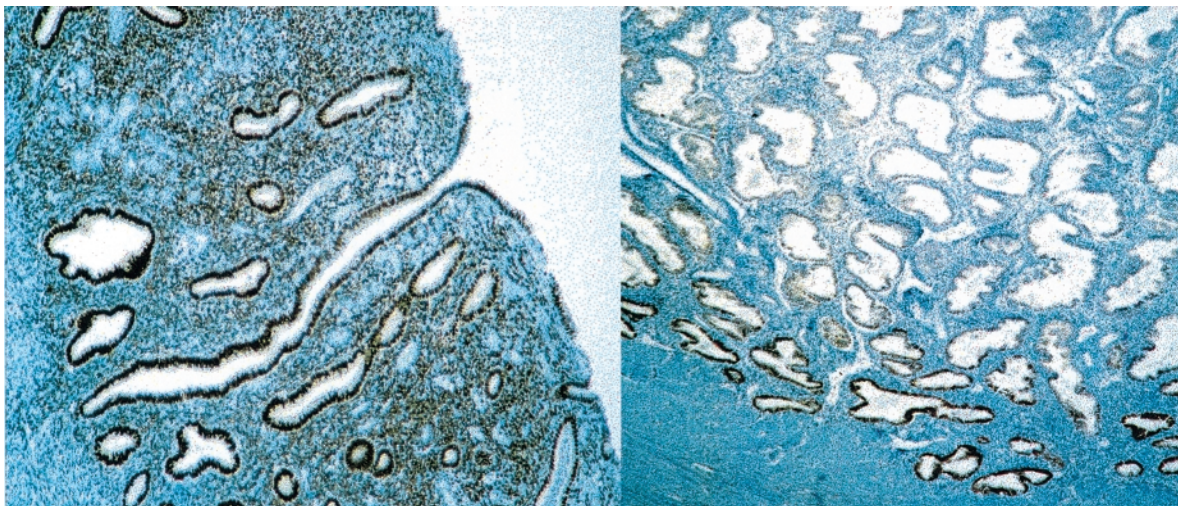


Figure 1. Immunocytochemistry of estrogen receptor (ER) expression during the late proliferative ($\times 100$) (left) and late secretory phase ($\times 50$) (right) of the cycle. During the secretory phase of the cycle the positive ER staining is restricted to a small fringe representing zone IV basalis.

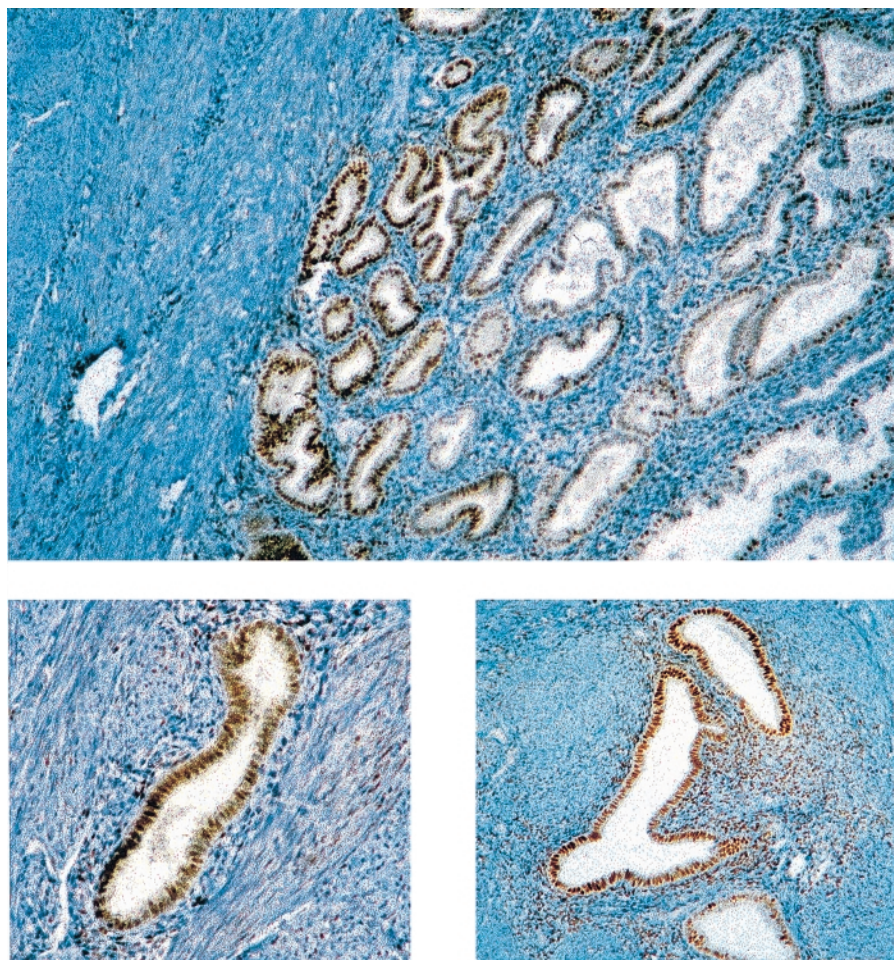


Figure 2. Immunocytochemistry of estrogen receptor (ER) expression during the late secretory phase in sections of the endometrium ($\times 100$) (top) and of adenomyotic ($\times 200$) (bottom left) and endometriotic ($\times 200$) (bottom right) lesions of the same patient. The endometriotic and adenomyotic lesions display the same positive ER staining as the deep basalis, while the spongy layer and the upper basalis is ER negative.

\pm SEM) and displayed, by light microscopy, the morphological characteristics of the basalis. In women with endometriosis this fringe of positive staining was broader (0.8 ± 0.19 mm; mean \pm SEM) in width ($P < 0.05$).

Figure 1 shows representative sections of the endometrium of healthy women in the late proliferative and in the late secretory phase of the cycle respectively, immunostained for ER. During the proliferative phase of the cycle the ER of the

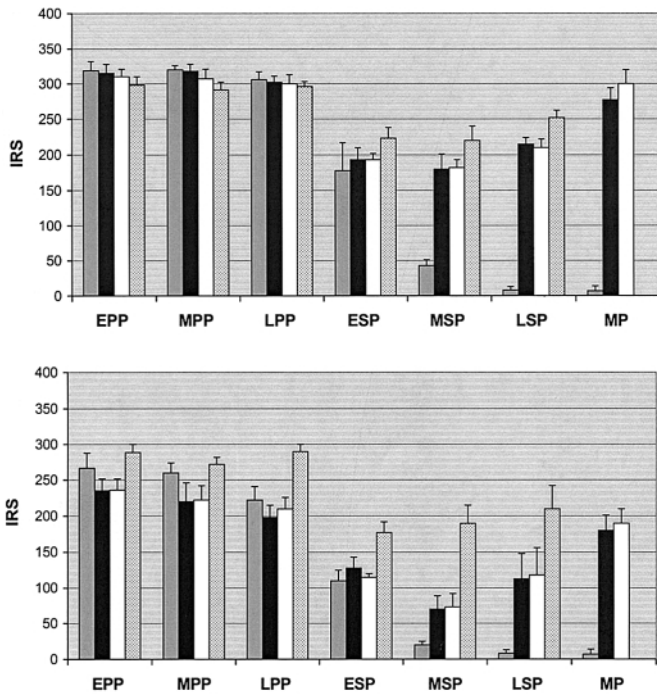


Figure 3. Histograms of the immunoreactive scores (IRS) of estradiol receptor expression (ER) in the epithelium (top) and the stroma (bottom) of the functionalis (grey bars), of zone IV basal (black bars), of adenomyotic (white bars) and of endometriotic (stippled bars) lesions during the early, mid- and late proliferative and secretory phases of the cycle respectively, and during the menstrual period (+SEM).

endometrial epithelium and the stroma are evenly distributed over all endometrial zones, whereas, during the late secretory phase, positive staining for epithelial and stromal ER is confined to the small basal endometrial fringe.

Figure 2 shows representative sections of immunostaining for ER in the endometrium, in an adenomyotic and endometriotic lesion respectively of the same patient in the late secretory phase of the cycle. In the endometrium, positive staining for ER is confined to the basal layer, whereas the functionalis and the lamina spongiosa are devoid of ER expression. The endometriotic and adenomyotic lesions showed, similar to the basal layer, positive immunostaining for ER expression. Light microscopically, the endometriotic and adenomyotic glands and stromal cells resembled those of the basal endometrium.

Figures 3 and 4 summarize the data obtained plotted as IRS for ER and PR expression, in both epithelium and stroma, in the eutopic endometrium of women with endometriosis and in endometriotic and adenomyotic lesions throughout the menstrual cycle. With respect to the hormone receptor expression in the eutopic endometrium there was no difference between the IRS of women without (data not shown) and with endometriosis. IRS of ER expression (Figure 3) were high for both epithelium and stroma in the functionalis and the basal layer of the eutopic endometrium throughout the proliferative phase. In the functionalis, including the spongiosa, the IRS of ER in the epithelium and stroma fell sharply during the early and mid-secretory phase to nearly undetectable levels in the late secretory and early menstrual phase. Also in the basal layer

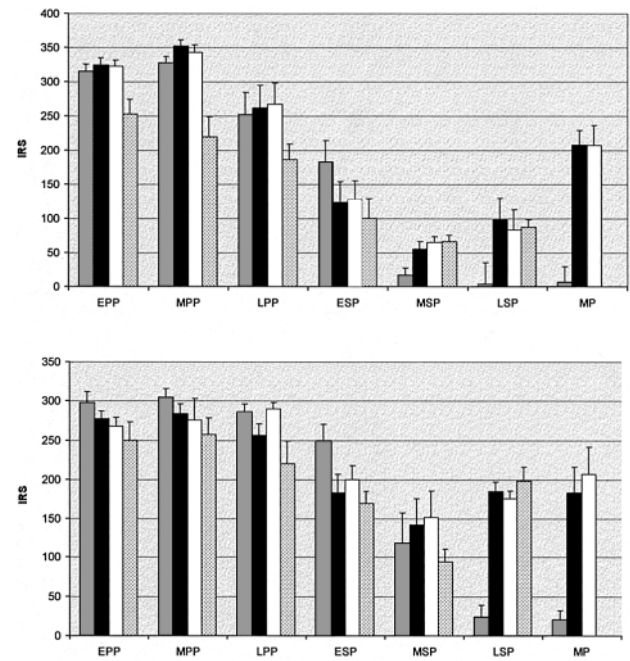


Figure 4. Histograms of the immunoreactive scores (IRS) of progesterone receptor expression (PR) in the epithelium (top) and the stroma (bottom) of the functionalis (grey bars), of zone IV basal (black bars), of adenomyotic (white bars) and of endometriotic (dotted bars) lesions during the early, mid- and late proliferative and secretory phases of the cycle respectively, and during the menstrual period (+SEM).

the IRS of ER expression fell with the onset of the secretory phase in both stroma and epithelium, but they declined only to intermediate levels with the IRS of the epithelium remaining on a higher level than those of the stroma. While during the secretory phase the IRS of ER expression in the functionalis progressively declined until menstruation, in the basal layer, they rose again, after the initial early secretory decline, towards the end of the cycle.

The IRS of PR expression in the functionalis and the deep basal layer respectively, followed essentially similar cyclical patterns as those of the ER expression except for the fact that the IRS PR expression were higher in the stroma than in the epithelium of the basal layer during the secretory phase (Figure 4).

The cyclical patterns of the IRS of ER and PR expression in endometriotic and adenomyotic lesions completely mimicked those of the deep basal layer with the exception of the IRS of ER expression in the stroma of endometriotic lesions, which were higher than those of the basal and adenomyotic stroma during the secretory phase with the difference reaching significance ($P < 0.05$) in the mid-secretory phase (Figure 3, bottom).

PR_B expression was positive during the proliferative phase in the epithelium of both functionalis and basal layer of the eutopic endometrium and in the epithelium of endometriotic and adenomyotic lesions, while it was only faint or negative in the stroma of the respective tissue specimens. During the secretory phase, staining for PR_B expression was in general faint or negative in both epithelium and stroma of these tissue specimens. Since immunostaining for PR expression, representing both isoforms, is positive in the stroma of the basal layer and of endometriotic and adenomyotic lesions, the respective PR

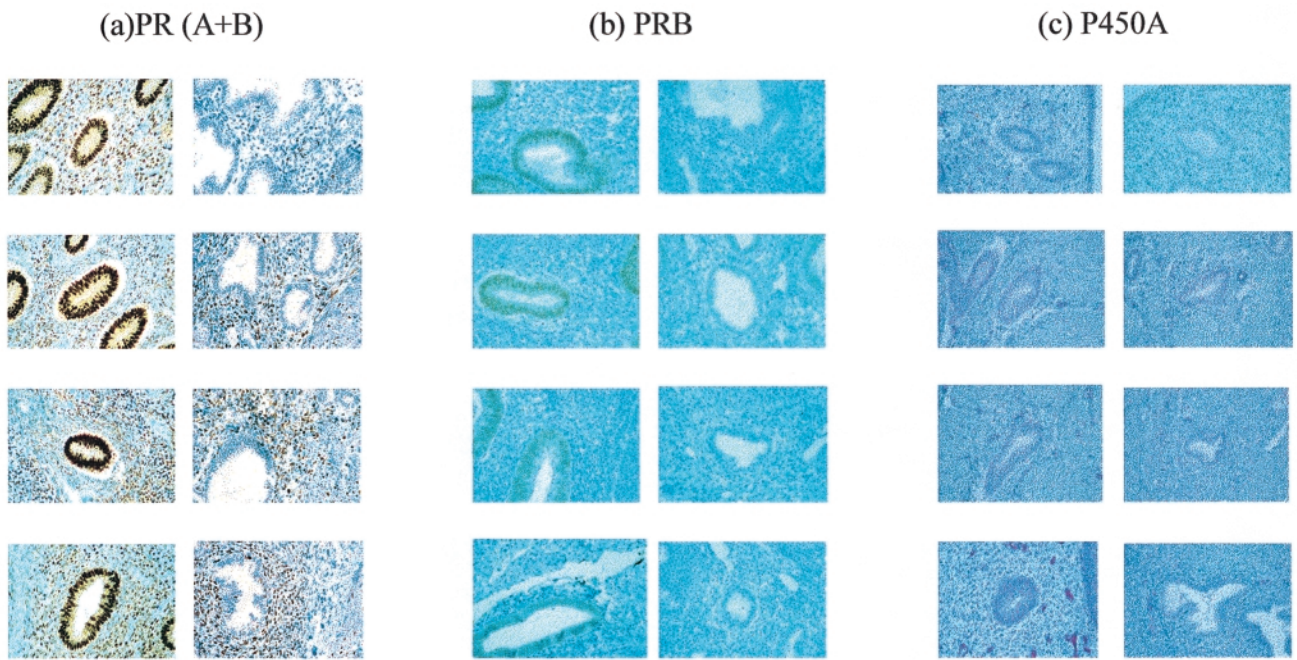


Figure 5. Immunohistochemistry of progesterone receptor (PR) ($\times 400$) (a) and progesterone receptor isoform B (PR_B) ($\times 400$) (b) expression and of P450 aromatase expression ($\times 400$) (c) (light pink staining of the epithelium) during the proliferative (left sections of a–c) and late secretory phase (right sections of a–c) of the cycle in (from top to the bottom) the functionalis, the basalis of the eutopic endometrium and in adenomyotic and endometriotic lesions.

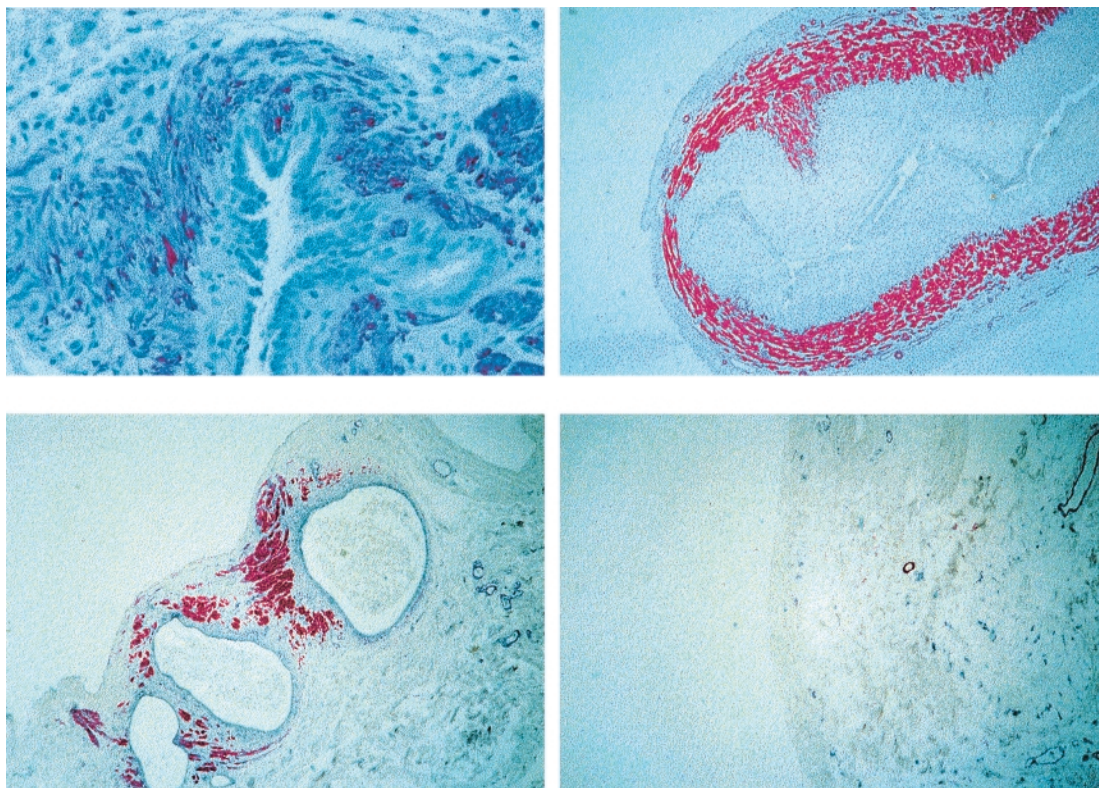


Figure 6. Specific actin immunochemistry of a section of a peritoneal endometriotic lesion ($\times 400$) (top left), of a section of a fetal primordial uterus of the 23rd week of pregnancy ($\times 50$) (top right), of a peritoneal endometriotic lesion ($\times 50$) (bottom left) and of the adjacent unaffected peritoneum ($\times 100$) (bottom right).

are considered to represent the PR_A isoform. Representative sections are shown in Figure 5a,b.

Immunohistochemistry of P450A exhibited, according to the 4-point scale, ‘moderate’ staining in both basalis and

functionalis of the eutopic endometrium and in endometriotic and adenomyotic lesions throughout the proliferative phase. In the functionalis, immunostaining of P450A gradually declined during the early and mid- and became negative in the late

Table II. Immunohistochemical expression of estrogen receptor (ER), progesterone receptor (PR), PR_B and P450 aromatase in endometrial tissue fragments of menstrual blood of women with and without endometriosis

Parameter	Healthy controls		Endometriosis		P (Fisher's test)
	Positive/n	%	Positive/n	%	
ER (epithelium and stroma)	2/19	10	18/24	75	< 0.05
PR (epithelium)	0/19	0	8/24	33	< 0.05
PR (stroma)	2/19	10	14/24	58	< 0.05
PR _B (epithelium and stroma)	0/19	0	0/24	0	NS
P450 aromatase (epithelium and stroma)	2/19	10	20/24	83	< 0.05

NS = not significant.

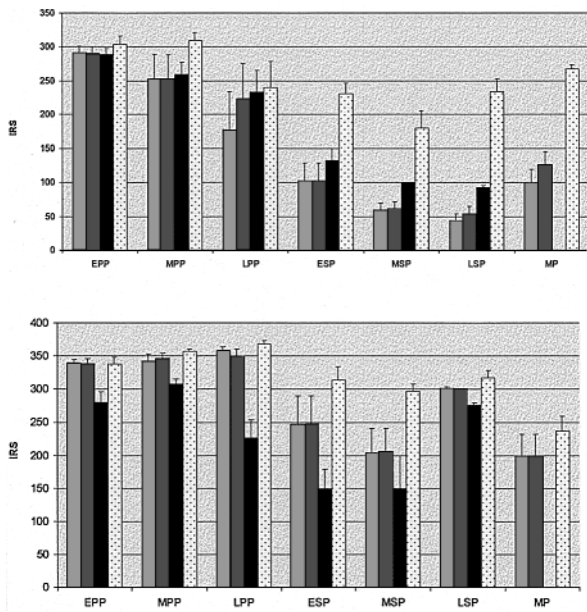


Figure 7. Histograms of the immunoreactive scores (IRS) of estradiol (ER) (top) and progesterone (PR) receptor expression (bottom) in the archimyo (□) and in the muscular tissue of adenomyotic (■) and of endometriotic (■) lesions and of the stratum vasculare (▨) of the outer myometrium during the early, mid- and late proliferative and secretory phases of the menstrual cycle respectively, and during the menstrual period (+SEM).

secretory phase. In the basalis and in adenomyotic lesions the immunostaining fell only to 'weak' levels in the late secretory phase. In endometriotic lesions the staining remained nearly at the 'moderate' level throughout the secretory phase. Representative sections are shown in Figure 5c.

All endometriotic lesions studied (*n* = 35) showed peristromal smooth muscle cells with specific smooth muscle cell actin immunohistochemistry. Figure 6 shows two representative sections of peritoneal endometriotic lesions stained for smooth muscle cells. For comparison, a sagittal section of a fetal uterus of the 23rd week of gestation and unaffected peritoneum are shown.

Figure 7 shows the cyclical patterns of the IRS of ER and PR expression of the muscular tissue of endometriotic and adenomyotic lesions in comparison with the respective patterns of the archimyo and stratum vasculare of the uterine

muscular wall. During the proliferative phase of the cycle, ER expression is high in all the muscular tissues tested. During the secretory phase there is a parallel decrease in the IRS of ER expression in the archimyo and the smooth muscle components of the endometriotic and adenomyotic lesions, while the IRS remain on a relatively high level in the stratum vasculare. The IRS of PR expression are high in all tissues tested. The IRS of the stratum vasculare exhibit only a slight decrease during the secretory phase with a further significant decrease during the menstrual phase. The IRS of PR expression of the archimyo and of the muscular component of the adenomyotic lesions displays with respect to both, the cyclical pattern and the absolute values a striking parallelism. The IRS of PR expression in the peristromal smooth muscle cells of endometriotic lesions show the same cyclical pattern as the archimyo but the absolute values are lower throughout the cycle with a significant difference (*P* < 0.05) in the late proliferative phase. The scores of the archimyo and the muscular components of both ectopic lesions exhibit a strikingly parallel and significant increment during the late secretory phase (*P* < 0.05) (Figure 7, bottom).

In the menstrual blood of women with and without endometriosis, endometrial tissue fragments could be identified that displayed the morphological and immunohistochemical characteristics of the basal endometrium. The prevalence of such a finding, however, was high in women with endometriosis and low in women without the disease (Table II).

Figure 8 shows representative sequential sections of endometrial tissue fragments of menstrual blood stained for ER, PR, PR_B and P450A expression respectively from a woman without (Figure 8, left series) and a woman with (Figure 8, middle and right series) endometriosis. The tissue fragment obtained from the menstrual blood of the healthy woman displays the morphological characteristics of late secretory functionalis. The sequential sections of this series were all negative with respect to the expression of ER, PR, PR_B and P450A.

The middle and right series of Figure 8 show representative sequential sections of two endometrial tissue fragments that stain positive for ER, PR and P450A that were taken from the same menstrual blood specimen of a woman with endometriosis. The sections clearly show that the fragments display

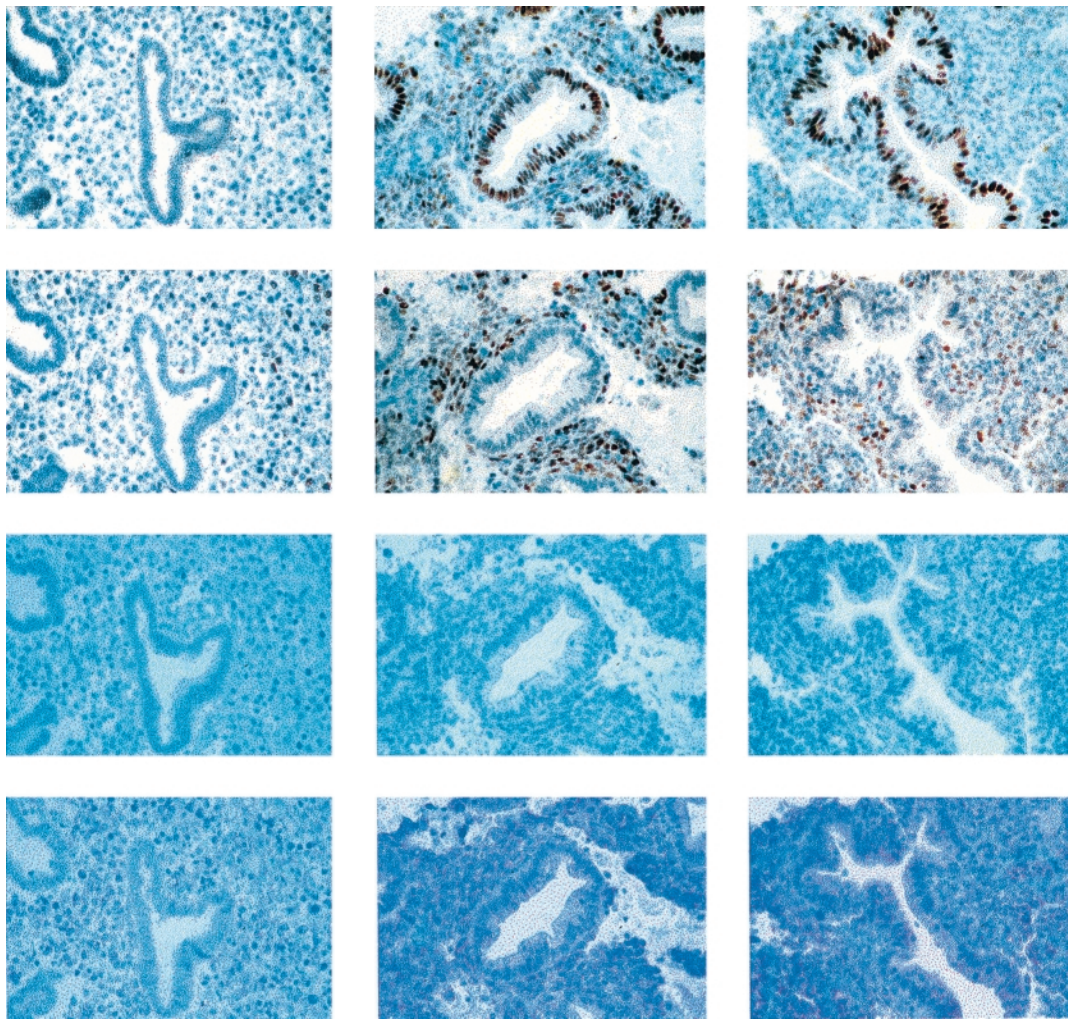


Figure 8. Immunohistochemistry of estrogen receptor (ER), progesterone receptor (PR), progesterone receptor B isoform (PR_B) and P450 aromatase expression (from top to bottom, ×400) in endometrial tissue fragments of antegradely shed menstrual blood of a woman without (left) and with (middle and right) endometriosis. Each series comprises sequential sections of individual endometrial tissue fragments. The two series of the woman with endometriosis are taken from the same menstrual blood specimen and show that one tissue fragment (middle sections) exhibits more staining for ER and PR in stroma. The negative staining for PR_B suggests that the stromal progesterone receptors constitute the PR_A isoform.

the morphological characteristics of the basalis. Both series differ only with respect to the ER and PR staining of the stroma, which is stronger in the middle versus the right series.

Discussion

The presented data show that ectopic endometrial lesions such as endometriosis and adenomyosis mimic, with respect to immunohistochemical parameters studied, the respective immunohistochemical parameters of the basal endometrium and archimyometrium during the menstrual cycle. Endometriotic lesions were often described as ‘out of phase’ in comparison with the eutopic endometrium (Jänne *et al.*, 1981; Brosens *et al.*, 1994). This study shows that they are ‘in phase’ with the basal endometrium. Furthermore, it is demonstrated that endometrial fragments of the basalis are shed during menstruation with a higher prevalence in women with endometriosis than in those without the disease. These data support our view that endometriosis is, like adenomyosis, primarily a uterine disease (Leyendecker *et al.*, 1996, 1998; Kunz *et al.*,

2000a; Leyendecker, 2000) and provide strong circumstantial evidence that peritoneal endometriotic lesions result from the dislocation and implantation of fragments of basal endometrium.

Present information of the hormone receptor expression in the basal layer are mainly derived from studies that have been performed in the rhesus monkey (Okulicz *et al.*, 1993; Brenner and Slayden, 1994). No information at all is available that relates endometriotic lesions to the basal layer of the endometrium. All previous studies that compared the ER and PR expression in endometriotic lesions with the respective hormone receptor expression in the eutopic endometrium utilized transcervical biopsies (Jänne *et al.*, 1981; Bergqvist and Fernö, 1993; Nisolle *et al.*, 1994) that may have missed basal endometrium or did not take basal endometrium separately into consideration (Jones *et al.*, 1995).

A quadripartite horizontal zonation exists in the human endometrium and in that of menstruating non-human primates. The four endometrial zones (Bartelmez, 1957) are micro-environments that differ by position, ultrastructural

differentiation and mitotic activity during the cycle (Kaiserman-Abramof and Padykula, 1987; Padykula *et al.*, 1989). During the secretory phase of the rhesus menstrual cycle, functionalis zones I and II (henceforth functionalis) and basalis zone III (henceforth spongiosa) are characterized by progesterone-induced mitotic inhibition, while basalis zone IV (henceforth basalis) not only escapes from that inhibition but rather exhibits increasing mitotic activity towards the end of the secretory phase (Padykula *et al.*, 1989). It is reasonable to assume that these data are also pertinent to the human endometrium. Our data show that, in the human, proliferative phase ER and PR as well as P450A expression persist, though each at different levels, in the epithelium and/or the stroma of the basalis during the whole secretory phase, with even a slight increase with respect to the ER and PR expression during the late secretory phase. In the functionalis and in the spongiosa, however, the IRS of ER and PR expression and the immunostaining for P450A decline progressively towards the end of the cycle. With respect to the ER and PR expression these data concur with findings in the rhesus monkey (Okulicz *et al.*, 1993; Brenner and Slayden, 1994) and extend those obtained in the human (Coppens *et al.*, 1993) but do not concur in part with findings of Koshiyama *et al.* (1995) who used cryostat sections in their study. Furthermore, there is indirect evidence (Wang *et al.*, 1998; Nisolle *et al.*, 1999) that the PR in the endometrial stroma of the basalis constitutes the PR_A isoform, concurring with other data (Mote *et al.*, 2000). Thus, the basalis appears to constitute a highly vital endometrial compartment throughout the menstrual cycle, while most of the other layers are destined to cell death concomitant with the late luteal progesterone decline (Padykula *et al.*, 1989).

There was no difference with respect to the patterns of the IRS of ER and PR and of P450A expression respectively, of all endometrial layers between women with and without endometriosis. We could not confirm recent data (Kitawaki *et al.*, 1999) suggesting that the diagnosis of endometriosis could be based on the immunohistochemical presence of P450A in the epithelium of endometrial biopsies.

It is assumed that during menstruation, in the non-human primate, only the more superficial layers are shed (Brenner and Slayden, 1994; Rudolph-Owen *et al.*, 1998). One study has claimed that an appreciable fraction of the stratum spongiosum disintegrates and disappears during menstruation in the human with a considerable variation in degree of endometrial shedding between uteri and even in different areas of the same uterine specimen (McLennan and Rydell, 1965). In this study we demonstrate that endometrial tissue fragments that are derived from the basalis are shed during menstruation. This is the case in women with and without endometriosis. The amount of endometrial tissue fragments derived from the basalis, however, is significantly higher in menstrual blood of women with endometriosis than without the disease.

Thus, the normal level of desquamation must be localized in the spongiosa close to the basalis with the consequence that normally no, or only a few, tissue fragments of the basal layer are desquamated. Desquamation is considered to be associated with the endometrial up-regulation of endometrial matrix

metalloproteinases (MMP) at the end of the secretory phase (Osteen *et al.*, 1994; Rudolph-Owen *et al.*, 1998). Probably due to a zone-specific up-regulation of the MMP, which involves roughly the upper third of the endometrium (Rudolph-Owen *et al.*, 1998), the level of desquamation within the spongy layer is ensured.

Recently, it was shown that uterine endometrium from women with endometriosis expressed significantly higher levels of MMP-9 and lower levels of tissue inhibitors of metalloproteinases than that of women without the disease (Chung *et al.*, 2001). It is therefore possible that a dysregulation of the control mechanisms of MMP expression results in an alteration of the zone-specific regulatory tissue gradients with the involvement of the basalis.

Alternatively, the increased detachment of fragments of basal endometrium in women with endometriosis may be primarily mechanical or traumatic in nature. Women with endometriosis display a considerable degree of uterine hyperperistalsis with a doubling of the peristaltic frequency during the early and mid-proliferative phases of the cycle (Salamanca and Beltran, 1995; Leyendecker *et al.*, 1996) and a considerably increased intrauterine pressure (Mäkäräinen, 1988; Bulletti *et al.*, 1997), which may facilitate the detachment of basal tissue fragments during menstruation.

Furthermore, in women with endometriosis, due to hyperperistalsis retrograde uterine transport capacity is markedly increased during menstruation and the early proliferative phase of the cycle (Salamanca and Beltran, 1995; Kunz *et al.*, 1996; Leyendecker *et al.*, 1996; Kunz *et al.*, 2000b). One may therefore assume that, due to both increased detachment and increased retrograde transport, the peritoneal load with endometrial fragments of the basalis is much higher in women with endometriosis in comparison with women without the disease.

There is no direct proof available but it is reasonable to assume that the endometriotic peritoneal lesions result from the implantation and growth of retrogradely shed basalis rather than from shed functionalis. Strong support for this assumption, however, comes from the observation that all endometriotic lesions exhibit peristromal smooth muscle cells (Anaf *et al.*, 2000) (Figure 6). The ability to form smooth muscle cells is a property of the basal endometrium at the endometrial-myometrial junction (Bird and Willis, 1965; Fujii *et al.*, 1989). Moreover, with the cyclical pattern of ER and PR expression (Figure 7) the peristromal smooth muscle tissue displays characteristics of the archimyometrium, which itself is derived from the endometrial mesenchyme during uterine organogenesis (Werth and Grusdew, 1898; Konishi *et al.*, 1984; Noe *et al.*, 1999). Thus, the peristromal smooth muscle cells may constitute a tissue component of the endometriotic lesion that is homologous to the archimyometrium. This becomes particularly apparent with the parallel increase of the IRS of PR expression in the smooth muscle cells of the ectopic lesions and the archimyometrium respectively, during the late secretory phase. This increase is, with respect to the archimyometrium, most probably related to the function of inducing peristaltic quiescence during this phase of the cycle (Figure 7) (Kunz *et al.*,

2000b). These data and considerations suggest that endometriosis is derived from implants of basal endometrium that have the capacity to reconstruct all components of the archimera (Noe *et al.*, 1999) such as endometrial epithelium and stroma as well as archimyometrium (Figure 6). According to experiments in the rodent, this 'stem cell potential' of fragments of the basal endometrium requires epithelial-mesenchymal integrity of the implants (Cunha *et al.*, 1989).

Previous studies have suggested that endometriotic lesions differ from eutopic endometrium in various respects, such as the expression of *P450A* (Prefontaine *et al.*, 1990; Noble *et al.*, 1996; Kitawaki *et al.*, 1997), of the 17 β steroid dehydrogenase type 2 (17 β -HSD 2) (Zeitoun *et al.*, 1998) and of the PR_A isoform (Attia *et al.*, 2000). Sequential sections of paraffin-embedded specimens of menstrual blood stained for ER, PR, PR_B and *P450A* expression demonstrate that the biochemical features suggested to be characteristic of endometriotic lesions, such as PR_A isoform (subtractive inference; Wang *et al.*, 1998) and *P450A* expression, are present in endometrial tissue fragments representing the basalis (Figure 8). Mote *et al.* could demonstrate that in the deeper basalis there was a predominance of the expression of the PR_A isoform and a relative lack of the PR_B isoform, while the functionalis and the upper basalis expressed similar relative concentrations of PR_A and PR_B (Mote *et al.*, 2000). Thus, assumed characteristics of the endometriotic lesions such as the preferential expression of *P450A* and PR_A isoform and possibly also the lack of expression of 17 β -HSD type 2 during the secretory phase of the cycle may stem from the deep basalis as the parent tissue.

The finding of a significantly elevated ER expression in the stroma of endometriotic lesions in particular during the secretory phase, which was paralleled to a lesser extent by the ER expression in the peristromal smooth muscle cells, deserves closer attention. This elevation was absolutely not paralleled by the ER expression in the epithelial endometrium and the PR expression in both epithelium and stroma of the lesions. It is therefore unlikely that this separate elevation of the ER expression is caused by inflammatory cytokines or other factors of the local peritoneal milieu. In our opinion, it is rather due to a process of selection that favours the peritoneal implantation of a subset of endometrial fragments with a high proliferative potential mediated by the stromal estrogen receptor. These fragments may also be equipped with an increased expression of *P450A*. One study (Mote *et al.*, 2000) described a surprising heterogeneity of the receptor expression between glands, which is also demonstrated in Figure 8 of our study, supporting this conjecture.

From a mere topographical point of view, it is evident that adenomyosis is derived from the basal endometrium. With respect to all parameters used in this study the endometrium of adenomyotic lesions completely mimicked the basal endometrium. Also the myometrium surrounding adenomyotic lesions paralleled the archimyometrium with respect to the cyclical pattern of ER and PR expression (Figure 7). It is therefore likely that the myometrium directly adjacent to the adenomyotic lesions results from metaplasia of adenomyotic

stroma into smooth muscle cells as already suggested (Bird and Willis, 1965) and is therefore paramesonephric in character and homologous to the archimyometrium. The diagnosis of adenomyosis by magnetic resonance imaging is essentially based on this metaplastic process (Brosens *et al.*, 1995; Brosens and Brosens, 2000; Kunz *et al.*, 2000a).

In conclusion, the data of this paper add further support to our previous notion that endometriosis is, like adenomyosis, primarily a disease of the archimera (Leyendecker *et al.*, 1998; Leyendecker, 2000). There is strong circumstantial evidence that both endometriosis and adenomyosis are derived from the basal layer of the endometrium. Furthermore, we propose that dislocated basal endometrium has stem cell character capable of resuming embryonic growth potential and resulting in the ectopic formation of all archimerial components such as epithelium, stroma and paramesonephric smooth muscle cells. In women with early onset endometriosis and adenomyosis, the dislocation of the basal endometrium most probably results from auto-traumatization by uterine hyperperistalsis as a dysfunction of the uterine mechanism of rapid sperm transport (Kunz *et al.*, 1996; Leyendecker *et al.*, 1996). The biological mechanisms that govern normo- and hyperperistalsis, however, remain to be elucidated.

References

- Anaf, V., Simon, P., Fayt, I. and Noel, J. (2000) Smooth muscles are frequent components of endometriotic lesions. *Hum. Reprod.*, **15**, 767-771.
- Attia, G.R., Zeitoun, K., Edwards, D., Johns, A., Carr, B.R. and Bulun, S.E. (2000) Progesterone receptor isoform A but not B is expressed in endometriosis. *J. Clin. Endocrinol. Metab.*, **85**, 2897-2902.
- Bartelmez, G.W. (1957) The phases of the menstrual cycle and their interpretation in terms of the pregnancy cycle. *Am. J. Obstet. Gynecol.*, **74**, 931-955.
- Bartosik, D., Jakobs, S.L. and Kelly, L.J. (1986) Endometrial tissue in peritoneal fluid. *Fertil. Steril.*, **46**, 796-800.
- Bergqvist, A. and Fernö, M. (1993) Oestrogen and progesterone receptors in endometriotic tissue and endometrium: comparison of different cycle phases and ages. *Hum. Reprod.*, **8**, 2221-2227.
- Bird, C.C. and Willis, R.A. (1965) The production of smooth muscle by the endometrial stroma of the adult human uterus. *J. Path. Bact.*, **90**, 75-81.
- Brenner, R.M. and Slayden, O.D. (1994) Cyclic changes in the primate oviduct and endometrium. In Knobil, E. and Neill, J.D. (eds), *The Physiology of Reproduction*. Raven Press, New York, pp. 541-569.
- Brosens, I.A. and Brosens, J.J. (2000) Redefining endometriosis: is deep endometriosis a progressive disease? *Hum. Reprod.*, **15**, 1-3.
- Brosens, I., Vasquez, G., Deprest, J. and Puttemans, P. (1994) Pathogenesis of endometriosis. In Nezhat, C.R., Berger, G.S., Nezhat, F.R., Buttram, V.C. Jr and Nezhat, C.H. (eds), *Endometriosis—Advanced Management and Surgical Techniques*. Springer-Verlag, New York.
- Brosens, J.J., de Souza, N.M. and Barker, F.G. (1995) Uterine junctional zone: function and disease. *Lancet*, **346**, 558-560.
- Bulletti, C., Rossi, S., de Ziegler, D., Massoneau, M., Polli, V., Negrini, V., de Mounstler, B. and Flamigni, C. (1997) The uterine contractility in endometriosis. *International Meeting on Infertility and Assisted Reproductive Technology, Porto Cervo, Italy, June 11-14, 1997*. Abstract Book, page 129.
- Chung, H.W., Wen, Y., Hun, S.H., Nezhat, C., Woo, B.H. and Lake Polan, M. (2001) Matrix metalloproteinase-9 and tissue inhibitor of metalloproteinase-3 mRNA expression in ectopic and eutopic endometrium in women with endometriosis: a rationale for endometriotic invasiveness. *Fertil. Steril.*, **75**, 152-159.
- Coppens, M.T., Dhont, M.A., De Boever, J.G., Serreyn, R.F., Vandekerckhove, D.A. and Roels, H.J. (1993) The distribution of oestrogen and progesterone receptors in the human endometrial basal and functional layer during the normal menstrual cycle. *Histochemistry*, **99**, 121-126.

- Cunha, G.R., Young, P. and Brody, J.R. (1989) Role of uterine epithelium in the development of myometrial smooth muscle cells. *Biol. Reprod.*, **40**, 861–871.
- Dallenbach-Hellweg, G and Poulsen, H. (1984) *Atlas der Histopathologie des Endometriums*. Springer-Verlag, Heidelberg.
- D'Hooghe, T.M., Bambra, C.S., Raeymaekers, B.M., De Jonge, I., Lauweryns, J.M. and Koninckx, P.R. (1995) Intrapelvic injection of menstrual endometrium causes endometriosis in baboons (Papio cynocephalus and Papio anubis). *Am. J. Obstet. Gynecol.*, **173**, 125–134.
- Dmowski, W.P., Ding, J., Shen, J., Rana, N., Fernandez, B.B. and Braun, D.P. (2001) Apoptosis in endometrial glandular and stromal cells in women with and without endometriosis. *Hum. Reprod.*, **16**, 1802–1808.
- Fujii, S., Konishi, I. and Mori, T. (1989) Smooth muscle differentiation at endometrio-myometrial junction. An ultrastructural study. *Virch. Archiv A Pathol. Anat.*, **414**, 105–112.
- Jänne, O., Kaupilla, A., Kokko, E., Lantto, T., Rönneberg, L. and Vihko, R. (1981) Estrogen and progesterin receptors in endometriosis lesions, comparison with endometrial tissue. *Am. J. Obstet. Gynaecol.*, **141**, 562–566.
- Jolicoeur, C., Boutouil, M., Drouin, R., Paradis, I., Lemay, A. and Akoum, A. (1998) Increased expression of monocyte chemotactic protein-1 in the endometrium of women with endometriosis. *Am. J. Pathol.*, **152**, 125–133.
- Jones, R.K., Bulmer, J.N. and Searle, R.F. (1995) Immunohistochemical characterization of proliferation, oestrogen receptor and progesterone receptor expression in endometriosis: comparison of eutopic and ectopic endometrium with normal cycling endometrium. *Hum. Reprod.*, **10**, 3272–3279.
- Kaiserman-Abramof, I.R. and Padykula, H.A. (1989) Ultrastructural epithelial zonation of the primate endometrium (rhesus monkey). *Am. J. Anat.*, **184**, 13–30.
- Kitawaki, J., Noguchi, T., Amatsu, T., Maeda, K., Tsukamoto, K., Yamamoto, T., Fushiki, S., Osawa, Y. and Honjo, H. (1997) Expression of aromatase cytochrome P450 protein and messenger ribonucleic acid in human endometriotic and adenomyotic tissues but not in normal endometrium. *Biol. Reprod.*, **57**, 514–519.
- Kitawaki, J., Kusuki, I., Koshiba, H., Tsukamoto, K., Fushiki, S. and Honjo, H. (1999) Detection of aromatase cytochrome P-450 in endometrial biopsy specimens as a diagnostic test for endometriosis. *Fertil. Steril.*, **72**, 1100–1106.
- Koks, C.A., Dunselman, G.A., de Goeij, A.F., Arends, J.W. and Evers, J.L. (1997) Evaluation of a menstrual cup to collect shed endometrium for in vitro studies. *Fertil. Steril.*, **68**, 560–564.
- Koks, C.A., Groothuis, P.G., Dunselman, G.A., de Goeij, A.F. and Evers, J.L. (1999) Adhesion of shed menstrual tissue in an in-vitro model using amnion and peritoneum: a light and electron microscopic study. *Hum. Reprod.*, **14**, 816–822.
- Konishi, I., Fujii, S., Okamura, H. and Mori, T. (1984) Development of smooth muscle in the human fetal uterus: an ultrastructural study. *J. Anat.*, **139**, 239–252.
- Koshiyama, M., Konishi, I., Nanbu, K., Nanbu, Y., Mandai, M., Komatsu, T., Yamamoto, S., Mori, T. and Fujii, S. (1995) Immunohistochemical localization of heat shock proteins HSP70 and HSP90 in the human endometrium: correlation with sex steroid receptors and Ki-67 antigen expression. *J. Clin. Endocrinol. Metab.*, **80**, 1106–1112.
- Kruitwagen, R.F.P.M., Poels, L.G., Willemsen, W.N.P., De Ronde, I.J.Y., Jap, P.H.K. and Rolland, R. (1991a) Endometrial epithelial cells in peritoneal fluid during the early follicular phase. *Fertil. Steril.*, **55**, 297–303.
- Kruitwagen, R.F.P.M., Poels, L.G., Willemsen, W.N.P., Jap, P.H.K., Thomas, C.M.G. and Rolland, R. (1991b) Retrograde seeding of endometrial cells by uterine-tubal flushing. *Fertil. Steril.*, **56**, 414–420.
- Kunz, G., Beil, D., Deininger, H., Wildt, L. and Leyendecker, G. (1996) The dynamics of rapid sperm transport through the female genital tract. Evidence from vaginal sonography of uterine peristalsis (VSUP) and hysterosalpingoscintigraphy (HSSG). *Hum. Reprod.*, **11**, 627–632.
- Kunz, G., Beil, D., Huppert, P. and Leyendecker, G. (2000a) Structural abnormalities of the uterine wall in women with endometriosis and infertility visualised by vaginal sonography and magnetic resonance imaging. *Hum. Reprod.*, **15**, 76–82.
- Kunz, G., Kissler, S., Wildt, L. and Leyendecker, G. (2000b) Uterine peristalsis: directed sperm transport and fundal implantation of the blastocyst. In Filicori, M. (ed.), *Endocrine Basis of Reproductive Function*. Monduzzi Editore, Bologna.
- Lessey, B.A., Killiam, A.S.P., Metzger, D.A., Haney, A.F., Greene, G.L. and McCarty, K.S. Jr (1988) Immunohistochemical analysis of human uterine estrogen and progesterone receptors throughout the menstrual cycle. *J. Clin. Endocrinol. Metab.*, **67**, 334–340.
- Leyendecker, G., Kunz, G., Wildt, L., Beil, D. and Deininger, H. (1996) Uterine hyperperistalsis and dysperistalsis as dysfunctions of the mechanism of rapid sperm transport in patients with endometriosis and infertility. *Hum. Reprod.*, **11**, 1542–1551.
- Leyendecker, G., Kunz, G., Noe, M., Herbertz, M. and Mall, G. (1998) Endometriosis: a dysfunction and disease of the archimetra. *Hum. Reprod. Update*, **4**, 752–762.
- Leyendecker, G. (2000) Endometriosis is an entity with extreme pleiomorphism. *Hum. Reprod.*, **15**, 4–7.
- Maas, J.W.M., Groothuis, P.G., Dunselman, G.A.J., de Goeij, A.F.P.M., Struijker-Boudier, H.A.J. and Evers, J.L.H. (2001) Development of endometriosis-like lesions after transplantation of human endometrial fragments onto chick embryo chorioallantoic membrane. *Hum. Reprod.*, **16**, 627–631.
- Mäkäräinen L. (1988) Uterine contractions in endometriosis: effects of operative and danazol treatment. *J. Obstet. Gynecol.*, **9**, 134–138.
- McLennan, C.E. and Rydell, A.H. (1965) Extent of endometrial shedding during normal menstruation. *Obstet. Gynecol.*, **26**, 605–621.
- Mote, P.A., Balleine, R.L., McGowan, E.M. and Clarke, C.L. (2000) Heterogeneity of progesterone receptors A and B in human endometrial glands and stroma. *Hum. Reprod.*, **15** (Suppl. 3), 48–56.
- Nisolle, M., Paindaveine, B., Bourdon, A., Berliere, M., Casanas-Roux, F. and Donnez, J. (1990) Histologic study of peritoneal endometriosis in infertile women. *Fertil. Steril.*, **53**, 984–988.
- Nisolle, M., Casanas-Roux, F., Wyns, C., de Menten, Y., Mathieu, P.E. and Donnez, J. (1994) Immunohistochemical analysis of estrogen and progesterone receptors in endometrium and peritoneal endometriosis: a new quantitative method. *Fertil. Steril.*, **62**, 751–759.
- Nisolle, M., Gillerot, S., Casanas-Roux, F., Squifflet, J., Berliere, M. and Donnez, J. (1999) Immunohistochemical study of the proliferation index, oestrogen receptors and progesterone receptors A and B in leiomyomata and normal myometrium during the menstrual cycle and under gonadotrophin-releasing hormone agonist therapy. *Hum. Reprod.*, **14**, 2844–2850.
- Noble, L.S., Simpson, E.R., Johns, A. and Bulun, S.E. (1996) Aromatase expression in endometriosis. *J. Clin. Endocrinol. Metab.*, **81**, 174–179.
- Noble, L.S., Takayama, K., Zeitoun, K.M., Putman, J.M., Johns, D.A., Hinshelwood, M.M., Agarwal, V.R., Zhao, Y., Carr, B.R. and Bulun, S.E. (1997) Prostaglandin E2 stimulates aromatase expression in endometriosis-derived stromal cells. *J. Clin. Endocrinol. Metab.*, **82**, 600–606.
- Noe, M., Kunz, G., Herbertz, M., Mall G. and Leyendecker, G. (1999) The cyclic pattern of the immunocytochemical expression of oestrogen and progesterone receptors in human myometrial and endometrial layers: characterization of the endometrial-subendometrial unit. *Hum. Reprod.*, **14**, 101–110.
- Okulicz, W.C., Balsamo, M. and Tast, J. (1993) Progesterone regulation of endometrial estrogen receptor and cell proliferation during the late proliferative and secretory phase in artificial menstrual cycles in the rhesus monkey. *Biol. Reprod.*, **49**, 24–32.
- Osteen, K.G., Rogers, W.H., Gaire, M., Hargrove, J.T., Gorstein, F. and Matrisian, L.M. (1994) Stromal epithelial interaction mediates steroidal regulation of metalloproteinase expression in human endometrium. *Proc. Natl Acad. Sci. USA*, **91**, 10129–10133.
- Padykula, H.A., Coles, L.G., Okulicz, W.C., Rapaport, S.I., Mc Cracken, J.A., King, N.W. Jr, Longcope, C. and Kaiserman-Abramof, I.R. (1989) The basal layer of the primate endometrium: a bifunctional germinal compartment. *Biol. Reprod.*, **40**, 681–690.
- Prefontaine, M., Shih, C., Pan, C.C. and Bhavnani, B.R. (1990) Applicability of the product isolation and the radiometric aromatase assays for the measurement of low levels of aromatase: lack of aromatase activity in the human endometrium. *J. Endocrinol.*, **127**, 539–551.
- Rudolph-Owen, L.A., Slayden, O.D., Matrisian, L.M. and Brenner, R.M. (1998) Matrix metalloproteinase expression in Macaca mulatta endometrium: evidence for zone-specific regulatory tissue gradients. *Biol. Reprod.*, **59**, 1349–1368.
- Salamanca, A. and Beltran, E. (1995) Subendometrial contractility in menstrual phase visualised by transvaginal sonography in patients with endometriosis. *Fertil. Steril.*, **64**, 193–195.
- Sampson, J.A. (1927) Peritoneal endometriosis due to the menstrual dissemination of endometrial tissue into the peritoneal cavity. *Am. J. Obstet. Gynaecol.*, **14**, 422–429.
- Sillem, M., Hahn, U., Coddington, C.C. 3rd, Gordon, K., Runnebaum, B. and Hodgen, G.D. (1996) Ectopic growth of endometrium depends on its

- structural integrity and proteolytic activity in the cynomolgus monkey (*Macaca fascicularis*) model of endometriosis. *Fertil. Steril.*, **66**, 468–473.
- Viville, B., Charnock-Jones, D.S., Sharkey, A.M., Wetzka, B. and Smith, S.K. (1997) Distribution of the A and B forms of the progesterone receptor messenger ribonucleic acid and protein in uterine leiomyomata and adjacent endometrium. *Hum. Reprod.*, **12**, 815–822.
- Wang, H., Critchley, H.O., Kelly, R.W., Shen, D. and Baird, D.T. (1998) Progesterone receptor subtype B is differentially regulated in human endometrial stroma. *Mol. Hum. Reprod.*, **4**, 407–412.
- Werth, R. and Grusdew, W. (1898) Untersuchungen über die Entwicklung und Morphologie der menschlichen Uterusmuskulatur. *Arch. Gynäkol.*, **55**, 325–409.
- Wingfield, M., Macpherson, A., Healy, D.L. and Rogers, P.A.W. (1995) Cell proliferation is increased in the endometrium of women with endometriosis. *Fertil. Steril.*, **64**, 340–346.
- Witz, C.A., Monotoya-Rodriguez, B.S. and Schenken, R.S. (1999) Whole explants of peritoneum and endometrium: a novel model of the early endometriosis lesion. *Fertil. Steril.*, **71**, 56–60.
- Zeitoun, K., Takayama, K., Sasano, H., Suzuki, H.A.T., Moghrabi, N., Andersson, S., Johns, A., Meng, L., Putman, M., Carr, B. *et al.* (1998) Deficient 17 β -hydroxysteroid dehydrogenase type 2 expression in endometriosis: failure to metabolize 17 β -estradiol. *J. Clin. Endocrinol. Metab.*, **83**, 4474–4480.

Submitted on November 7, 2001; resubmitted on April 23, 2002; accepted on May 30, 2002