

# Endometriosis: a dysfunction and disease of the archimetra

G.Leyendecker<sup>1,3</sup>, G.Kunz<sup>1</sup>, M.Noë<sup>1,2</sup>, M.Herbertz<sup>1,2</sup> and G.Mall<sup>2</sup>

<sup>1</sup>Departments of Obstetrics and Gynaecology and <sup>2</sup>Department of Pathology, Klinikum Darmstadt, Academic Teaching Hospital to the University of Frankfurt, 64283 Darmstadt, Germany

## TABLE OF CONTENTS

Introduction	752
The concept of the archimetra and its structure and function	753
Alterations of the archimetra in endometriosis	754
References	760

Endometriosis is considered primarily a disease of the endometrial–subendometrial unit or archimetra. The clinical picture of endometriosis characterises this disease as a hyperactivation of genuine archimetrial functions such as proliferation, inflammatory defence and peristalsis. While the aetiology of the disease remains to be elucidated, a key event appears to consist in the local production of extraovarian oestrogen by a pathological expression of the P450 aromatase. The starting event may consist in a hyperactivity of the endometrial inflammatory defence, a hyperactivity of the endometrial oxytocin/oxytocin receptor system or in the pathological expression of the P450 aromatase system itself. Regardless of which of these levels the starting event is localized in, they influence each other on both the level of the archimetra and the endometriotic lesions. Locally elevated oestrogen levels inevitably up-regulate the endometrial oxytocin mRNA and increased levels of oxytocin result in uterine hyperperistalsis, increased transtubal seeding of endometrial tissue fragments and finally subfertility and infertility by impairment of the uterine mechanism of rapid and sustained sperm transport. Locally increased levels of oestrogen lead, on both the level of the endometrial–subendometrial unit and the endometriotic lesion, to processes of hyperproliferation. These processes result, on the level of the uterus, in an infiltrative growth of elements of the archimetra into the neometra and, on the level of the endometriotic lesion, in

**infiltrative endometriosis. There is circumstantial evidence that trauma might be an important initial event that induces the specific biochemical and cellular responses of the archimetra. This model is able to explain both the pleiomorphic appearance of endometriosis and the, up until now, enigmatic infertility associated with mild and moderate endometriosis.**

*Key words:* archimetra/endometriosis/hyper- and dysperistalsis/hyperproliferation/infertility

## Introduction

The aetiology and pathogenesis of endometriosis, which is the ectopic occurrence of endometrial tissue, has been enigmatic from its very first description until today. In consequence, neither practicable preventive measures against its development nor a causal treatment of this condition exist. Current treatment focuses on the lesions by medical or surgical means, with the high probability of recurrence of the lesions. Endometriosis may be asymptomatic and diagnosed only during a sterility work-up or it may cause severe discomfort. In any event, this disease is of paramount clinical importance in gynaecology and reproductive medicine and therefore a focus of continuing basic and clinical research.

As a result of presently prevailing theories such as the theories of coelomic metaplasia and transtubal transport of endometrial tissue into the peritoneal cavity and the theory of Müllerian remnants (for review: Nisolle and Donnez, 1997), most of the research efforts in the past concentrated on the endometriotic lesions and their peritoneal environment. Of these theories, the model of tubal transplantation by means of retrograde menstruation has gained widest acceptance (Sampson, 1927). Since, however, almost all women with patent tubes experience retrograde menstruation and only a small but significant proportion of women develop endometriosis, and since therefore retrograde menstruation

<sup>1</sup>To whom correspondence should be addressed

*per se* cannot account for the development of endometriosis, additional mechanisms such as an obstruction of menstrual outflow or a diminished tonus of the utero-tubal junction, with both resulting in an increased retrograde menstruation, have been proposed (Nisolle and Donnez, 1997).

Recently, it became apparent that the eutopic endometrium shares alterations with the ectopic tissue that are not found in the eutopic endometrium of disease-free women. These findings have advanced the view that the primary defect in endometriosis would be located in the eutopic endometrium, and it has been proposed that cells and tissue elements derived from such an altered eutopic endometrium and shed into the peritoneal cavity would have a higher potential of implantation and growth on peritoneal surfaces and of development into endometriosis (Wingfield *et al.*, 1995; Noble *et al.*, 1996; 1997; Jolicoeur *et al.*, 1998). A major drawback of all theories and mechanisms proposed so far is that they are unable to explain the frequent association of mild and moderate endometriosis with subfertility and infertility and the latter's persistence after medical or surgical eradication of the lesions (Hull *et al.* 1986; Adamson and Pasta, 1994; Berqvist *et al.*, 1997).

Recently, we have been able to demonstrate that, in patients with endometriosis with the impairment of directed sperm transport, a fundamental uterine function in the process of reproduction is disturbed (Kunz *et al.*, 1996; Leyendecker *et al.*, 1996). These findings not only provided additional strong evidence that the dysfunction resulting in endometriosis is primarily located on the level of the uterus but also showed for the first time a compromise of uterine function in endometriosis that results in infertility.

In this communication we will attempt to present a model of the pathogenesis of endometriosis that is based on recent data from the literature as well as on our own results. We will incorporate into the model some of the pleiomorphic findings in endometriosis such as ectopic endometrial growth, structural changes within the uterus, and functional alterations such as the subfertility in mild endometriosis. This requires, first of all, a short review of some aspects of the structure of the uterus and of its functions in the very early process of reproduction.

### **The concept of the archimetra and its structure and function**

The uterus is composed of two different organs, the inner archimetra and the outer neometra (Noe *et al.*, 1999). Phylogenetically and ontogenetically, the archimetra or endometrial-subendometrial unit constitutes the oldest part of the uterus (hence its denomination) and is composed of the epithelial and stromal endometrium and the underlying

stratum subvasculare of the myometrium with a predominantly circular arrangement of muscular fibres. While both the endometrium and the subendometrial myometrium display a cyclic pattern of steroid hormone receptor expression, the two other layers of the myometrium, the outer stratum supravasculare with a predominantly longitudinal arrangement of muscular fibres and the stratum vasculare consisting of a three-dimensional mesh of short muscular bundles (Werth and Grusdew, 1898; Wetzstein, 1965), show a continuously high receptor expression throughout the cycle (Noe *et al.*, 1998). Only the archimetra is of paramesonephric origin, while the outer layers, the neometra, are of non-Müllerian origin (Werth and Grusdew, 1898). There is an intimate structural contact between the stratum subvasculare and the stratum vasculare in that the muscular fibres of the two layers blend (Werth and Grusdew, 1898). This transitional zone, which constitutes roughly the inner quarter of the stratum vasculare, exhibits an intermediate cyclic pattern of steroid receptor expression (Noe *et al.*, 1999).

The archimetra and the outer layers of the uterus have different functions during the process of reproduction. While the stratum supravasculare and the stratum vasculare, sequentially acquired during evolution in meeting the requirements for the appropriate forces during parturition (Noe *et al.*, 1999), only subservise the expulsion of the fetus, the archimetra has extra fundamental functions in the very early processes of reproduction. These functions may be summarized as proliferation and differentiation of the endometrium for implantation, uterine peristalsis for directed rapid and sustained sperm transport, and inflammatory defence. In order to meet these functions, the components of the archimetra, the epithelial and stromal endometrium as well as the subendometrial myometrium constantly undergo fundamental structural and biochemical changes throughout the cycle (Roberts *et al.*, 1988; Aplin, 1989; Fujii *et al.*, 1989; Guidice and Ferenczy, 1996; Noe *et al.*, 1998).

### **Uterine peristalsis**

Peristaltic activity of the non-pregnant uterus is a fundamental function in the process of reproduction and only recently it became apparent that an impairment of this function causes infertility (Kunz *et al.*, 1996, 1997; Leyendecker *et al.*, 1996; Wildt *et al.* 1998). Uterine peristalsis only involves the stratum subvasculare of the myometrium and exhibits cyclic changes in direction, frequency and intensity (DeVries *et al.*, 1990; Lyons *et al.*, 1991; Kunz *et al.*, 1996). Only during menstruation are the contraction waves with lowest frequency and intensity

directed towards the cervix, while during the other phases of the cycle, and with highest frequency and intensity during the periovulatory phase, cervico-fundal peristalsis prevails (Lyons *et al.*, 1991). Uterine peristalsis subserves vaginal discharge of the menstrual debris, retrograde menstruation and rapid as well as sustained sperm transport (Kunz *et al.*, 1996; Leyendecker *et al.*, 1996). Also high fundal implantation of the embryo is considered a function of uterine peristalsis (DeVries *et al.*, 1990).

During the follicular phase, cervico-fundal peristalsis is controlled by the rising tide of follicular oestradiol (Kunz *et al.*, 1998a), which induces within the archimetra a cascade of transcriptional events such as the expression of endometrial oxytocin mRNA and oxytocin receptor mRNA (Zingg *et al.*, 1995). Oxytocin has been shown to increase uterine peristaltic activity (Kunz *et al.*, 1998a). As soon as a dominant ovarian structure can be visualized by ultrasound, sperm transport is directed preferentially into the tube ipsilateral to the dominant follicle (Kunz *et al.*, 1996). Directed sperm transport by uterine peristalsis is made possible by the specific structure of the stratum subvasculare in the fundal and cornual region (Werth and Grudew, 1898; Noe *et al.*, 1999) as well as by the specific endocrine stimuli that reach the upper part of the uterus by means of the utero-ovarian counter-current system (Einer-Jensen, 1988) and that are superimposed on those reaching the uterus via the systemic circulation (Kunz *et al.*, 1998a; 1998b). This enables the uterus, although it has become an unpaired organ during evolution and embryogenesis, to function asymmetrically as a paired one.

### **Inflammatory defence**

Inflammatory defence may be regarded as a phylogenetically old and specific function of the endometrial-subendometrial unit in view of the fact that, in lower animals, the Müllerian ducts end in a cloaca and that, in the human, the cervical mucus does not act as a barrier for passive ascension of inert particles and spermatozoa in the early follicular phase (Kunz *et al.*, 1996) and in the luteal phase (Faundes *et al.*, 1981; Kunz *et al.*, 1998c; Wildt *et al.*, 1998) of the cycle. In the rodent, the endometrium secretes antibacterial polypeptides (Xu *et al.*, 1995). Mucins such as MUC1 (Hey *et al.*, 1994; Gipson *et al.*, 1997; Carson *et al.*, 1998) and monocyte chemotactic protein-1 (MCP-1) (Jolicoeur *et al.*, 1998) are expressed in human endometrium and there is an influx of bone marrow-derived white blood cells into the endometrium during the luteal phase. This system, together with MUC-1 that is also assumed to be of importance in the immunological regulation of implantation (Hey *et al.*, 1994; Surveyor *et al.*, 1995; Loke and King,

1996), is phylogenetically very old and has the characteristics of an immunological system for allo-recognition (Loke and King, 1996). As a consequence of the expression and secretion of MCP-1 and possibly other chemoattractors, the endometrial surface is colonized with neutrophils and macrophages (Harper, 1994; Leiva *et al.*, 1994). The uterine inflammatory defence system appears to be strongly influenced by ovarian steroids. This has been demonstrated for the expression of MUC-1 (Surveyor *et al.*, 1995) and the influx of natural killer cells into the endometrium (Loke and King, 1996; King *et al.*, 1998), and in the normal endometrium the chemotactic activity for macrophages is highest during the proliferative phase of the cycle (Leiva *et al.*, 1994). Expression of MCP-1, however, did not differ between the phases of the cycle in normal women (Jolicoeur *et al.*, 1998).

### **Alterations of the archimetra in endometriosis**

In patients with endometriosis, fundamental alterations of the archimetra can be demonstrated that involve the gross anatomical structure, cellular biochemistry, as well as specific functions such as uterine peristalsis and the inflammatory defence system. All these changes are most probably interrelated but the starting point or points of the disease remain to be elucidated.

### **The endometrium in endometriosis**

Recent research has focused on changes of the eutopic endometrium in women with endometriosis in comparison with endometrium of disease-free women. These range from gross morphological changes such as a polypoid appearance of the endometrium in hysterosalpingography (McBean *et al.*, 1996) to microscopic changes in immunocytochemistry such as an aberrant integrin expression (Lessey *et al.*, 1994), and biochemical changes such as over-expression of plasminogen activator receptor (Sillem *et al.*, 1997) and an abnormal endothelial, epithelial and stromal proliferation (Wingfield *et al.*, 1995). Increased proliferation may correspond to the finding that, *in vitro*, cells derived from endometrium of women with endometriosis secrete more CA 125 (McBean and Brumstedt, 1993) and that the concentration of CA 125 in the menstrual blood of such women is increased as compared with that in women without endometriosis (Takahashi *et al.*, 1990).

Furthermore, eutopic endometrium in endometriosis expresses complement C3 (Isaacson *et al.*, 1990) and shows an increased expression of interleukin-6 (Tseng *et al.*, 1996) and of heat shock proteins (Ota *et al.*, 1997). The endometrium in women with endometriosis exhibits the same inflammatory changes that have been found in the

peritoneal cavity and attracts macrophages (Leiva *et al.*, 1994; Ota *et al.*, 1996), which are, in the endometriotic lesions, attracted by MCP-1 (Arici *et al.*, 1997). This corresponds to the recent finding of an increased expression of MCP-1 in endometrium of women with endometriosis (Jolicoeur *et al.*, 1998).

In normal endometrium P450 aromatase is not expressed (Prefontaine *et al.*, 1990; Noble *et al.*, 1996; Kitawaki *et al.*, 1997). However, expression of this enzyme, which converts androgen such as androstenedione and testosterone into oestrone and oestradiol, could be demonstrated in the endometrium of women with endometriosis and in the stroma of endometriotic and in adenomyotic tissue and may result in an increased local concentration of oestrogen in this tissue (Yamamoto *et al.*, 1993; Noble *et al.*, 1996, 1997; Kitawaki *et al.*, 1997). This corresponds to the finding of elevated oestradiol concentrations in the menstrual blood of women with endometriosis and adenomyosis in contrast to those of healthy women, while the respective serum levels did not differ (Takahashi *et al.*, 1989).

### **The stratum subvasculare of the myometrium**

The stratum subvasculare comprises about one quarter of the whole thickness of the myometrial wall if measured sagittally in the posterior wall of the corpus uteri where its diameter is largest. In MR imaging, the stratum subvasculare appears as a hypodense halo surrounding the endometrium (Lee *et al.*, 1985; Brown *et al.*, 1991; Scutt *et al.*, 1991), initially considered to represent a hypodense interface between endometrium and myometrium and therefore termed the junctional zone (Hricak *et al.*, 1983). Also with high-resolution vaginal sonography, the stratum subvasculare can, as in MR imaging, be identified as a hypodensal zone 3–5 mm in width around the endometrium (Fleischer *et al.*, 1986; Kunz, *et al.*, 1998d).

In 30 patients with endometriosis, vaginal sonography revealed that the hypodensal zone was infiltrated and significantly enlarged in comparison with that of patients without endometriosis, and there was no correlation between the thickness and the stage of the endometriosis (Kunz, *et al.*, 1998). Since histological and immunocytochemical studies have not yet been performed concerning the structural changes of the myometrial wall in endometriosis, it cannot be stated whether the enlargement of the hypodensal zone represents merely an expansion of the stratum vasculare or an infiltration of muscular fibres of the stratum subvasculare into the stratum vasculare expanding the transitional zone. It could even represent an infiltration of other components of the archimetra such as endometrial glands and stroma as observed in adenomyosis (Brosens *et al.*, 1995, 1998). Since

the whole thickness of the myometrium is not changed in these patients in comparison with that of healthy women, an infiltration of the stratum vasculare by the stratum subvasculare and other archimetrial elements, rather than an expansion of the latter, is most likely. Preliminary morphological data suggest that there is, similar to adenomyosis, a focal endometrial infiltration into the stratum subvasculare as well as into the stratum vasculare of the myometrial wall (G.Kunz, M.Noë, M.Herbertz, G.Mall, G.Leyendecker, unpublished data).

### **Uterine hyper- and dysperistalsis**

Both an increased endometrial oestrogen concentration and the expansion of the stratum subvasculare or ion infiltration of endometrium into the stratum vasculare have a fundamental impact on uterine peristalsis. Locally increased oestrogen probably further up-regulates endometrial oxytocin mRNA (Zingg *et al.*, 1995) and the increasingly released oxytocin results in an intensified peristaltic stimulation of the circular muscles of the stratum subvasculare (Kunz *et al.*, 1998a). Since the endometrium has probably infiltrated the stratum vasculare the muscular mesh of the stratum vasculare is also stimulated and involved in contractile activity. Basal intrauterine pressure is thus increased (Mäkäräinen *et al.*, 1988; Bulletti *et al.*, 1997) to result in dysperistalsis in the late proliferative phase with convulsive contractions of the whole uterus and a complete break down of uterine sperm transport (Kunz and Leyendecker, 1996; Leyendecker *et al.*, 1996).

Hyperperistalsis and increased intrauterine pressure may also be responsible for the increased transtubal transport of endometrial cells and tissue fragments and their shedding in the peritoneal cavity. In the early mid-follicular phase of the cycle, and within 1 min after application, roughly 30% of the labelled particles are transported into the tubes; during the midfollicular phase, more than half of this amount is transported into the contralateral tube, where the pre-ovulatory isthmic mucous plug (Jansen, 1980) may not yet have been formed, so allowing transport into the peritoneal cavity (Leyendecker *et al.*, 1996). This rapid transport of inert particles demonstrates the enormous power of the uterine peristaltic pump in endometriosis, and it was therefore suggested that uterine hyper- and dysperistalsis constitute the mechanical factors for increased transtubal seeding of endometrial material in the peritoneal cavity rather than retrograde menstruation *per se* (Leyendecker *et al.*, 1996). Retrograde menstruation may be increased by uterine hyperperistalsis (Salamanca and Beltran, 1995), but hyper- and dysperistalsis may also abrade viable endometrial cells throughout the entire cycle (Leyendecker *et al.*, 1996).

Detached endometrial tissue fragments have been shown to be present in the tube by means of tubal flushing throughout the menstrual cycle (Bartosik *et al.* 1986; Kruitwagen *et al.*, 1991). In those patients with endometriosis, the incidence of the finding of iatrogenically refluxed endometrial cells was higher in the luteal phase than during the follicular phase (Bartosik *et al.*, 1986).

### **A model of the pathogenesis of endometriosis**

Our own data and information included in this review clearly indicate that it is primarily the endometrial–subendometrial unit or archimetra from where endometriosis evolves. A constant feature of endometriosis is its occurrence during the reproductive period of life, and thus its general dependence on oestrogenic stimulation. Endometriosis is associated with proliferative processes within and outside the uterus, with hyper- and dysperistalsis as dysfunctions of uterine sperm transport and with a hyperactivated inflammatory response on both the level of the eutopic endometrium and the ectopic lesions. Taken together, all these dysfunctions may be explained on the basis of an increased oestrogen stimulation. Since, however, serum concentrations of oestradiol in women with endometriosis and adenomyosis do not differ from those in normal women (Takahashi *et al.*, 1989; Leyendecker *et al.*, 1996), it is intriguing to consider locally elevated oestrogen concentrations as a consequence of the pathological expression of P450 aromatase (Noble *et al.*, 1996, 1997) as the key event in the development of endometriosis.

It has been shown that prostaglandin E<sub>2</sub> (PGE<sub>2</sub>) constitutes at present the most potent stimulator of the expression of cytochrome P450arom mRNA in endometrial stroma (Noble *et al.*, 1997). In animal experiments, oxytocin induces the production and release of prostaglandin E<sub>2</sub> and F<sub>2a</sub> from endometrial cells (Gross *et al.*, 1988; Danet-Desnoyers *et al.*, 1994; Kim and Fortier, 1995; Asselin *et al.*, 1996; Fuchs *et al.* 1996; Shemesh *et al.*, 1997). Thus, a hyperactivated autocrine/paracrine oxytocin (OT)/oxytocin receptor (OTR) system that exists within the cells of the endometrial epithelium (Takemura *et al.*, 1993; Zingg *et al.*, 1995) could be another key event. Since the OT/OTR system is up-regulated by oestrogen (Zingg *et al.*, 1995), the OT/OTR/PGE<sub>2</sub>/P450 aromatase system could be considered a feed-forward system on both the level of the endometrium and the endometriotic lesions (Figure 1). Expression of oxytocin mRNA has been demonstrated in endometriotic lesions (Mitzumoto *et al.*, 1995).

A hyperactivated endometrial inflammatory response could also be the key event in the development of endometriosis or could at least further stimulate its

progression. Attracted and activated monocytes/ macrophages secrete many angiogenic and other growth factors and stimulate stromal proliferation and the production of pro-inflammatory molecules (Halme *et al.*, 1988; Olive *et al.*, 1991; Braun *et al.*, 1996; McLaren *et al.*, 1996; Rana *et al.*, 1996). PGE<sub>2</sub> (Karck *et al.*, 1996) and cytokines may stimulate the expression of endometrial P450 aromatase (Noble *et al.*, 1997). In turn, elevated endometrial oestrogen may up-regulate the endometrial OT/OTR system (Zingg *et al.*, 1995), which stimulates in an autocrine fashion the production of prostaglandins that feedback on the endometrial inflammatory defence system and/or directly on the endometrial P450 aromatase. Locally elevated oestrogen could also directly stimulate the endometrial inflammatory defence system (Leiva *et al.*, 1994; Jolicoeur *et al.*, 1998). Furthermore, hyperactivation of the OT/OTR system would result in uterine hyperperistalsis, which could in turn activate the endometrial inflammatory defence system by constant trauma or constantly increased aspiration of debris and infectious particles into the uterine cavity.

This picture becomes even more complicated if it is taken into account that certain phenotypes of endometriotic disease show a prevalence with respect to age, in that ovarian endometrioma and recto-vaginal endometriosis are usually observed in younger women (Nisolle and Donnez, 1997) and adenomyosis is more frequently encountered in parous elder women (Parazzini *et al.*, 1997). Some women develop severe endometriosis following childbirth and some women present with mild-to-moderate endometriosis, with uterine hyper- and dysperistalsis being the reason for their primary sterility (Leyendecker *et al.*, 1996). Furthermore, the disease may be acquired or a genetic background may be involved (Malinak *et al.*, 1980; Simpson *et al.*, 1980; Kennedy *et al.*, 1997). Also environmental factors such as endocrine disruptors may play a role in the development of endometriosis (Rier *et al.*, 1993; Bois and Eskenazi, 1994; Koninckx *et al.*, 1994; Eskenazi and Kimmel, 1995; Mayani *et al.*, 1997) and, according to data from animal experiments, the oestradiol receptor and oxytocin receptor systems, may be involved (Tsai *et al.*, 1997).

In any event, an increased stimulation of the archimetrial oestrogen receptors, superimposed on the physiological one by ovarian steroids, appears to be crucial in the pathophysiology of endometriosis (Item 1, see Figure 1). This occurs irrespective of the various phenotypes of endometriosis and the possibly various aetiologies and starting events of the disease such as an intrinsically hyperactivated inflammatory response, intrinsically up-regulated OT/OTR system or an intrinsic pathological expression of P450 aromatase,

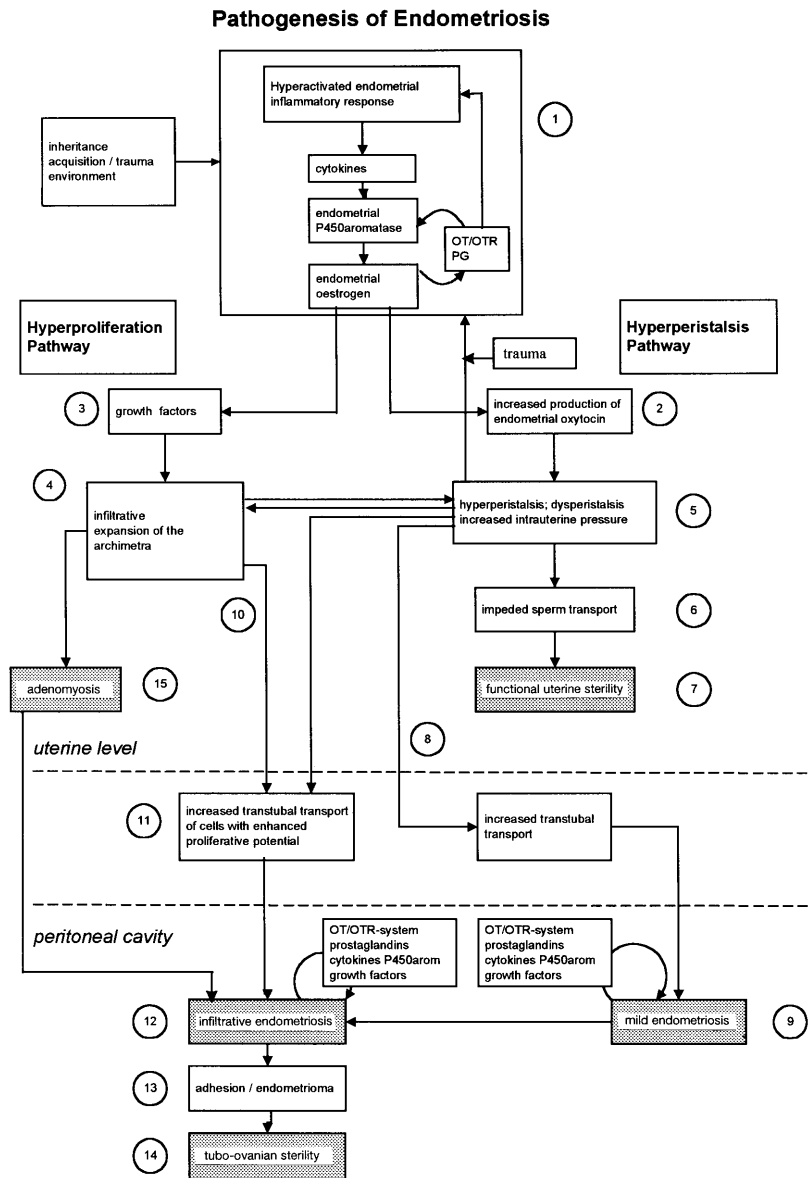
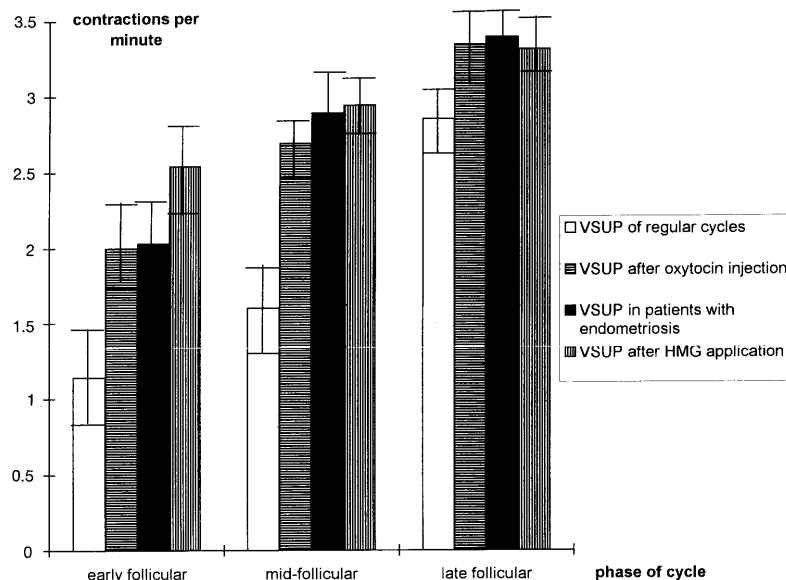


Figure 1. A schematic representation of the pathophysiology of endometriosis.

Locally increased tissue concentrations of oestradiol (Item 1, Figure 1) may further stimulate the up-regulation of endometrial oxytocin mRNA (Zingg *et al.*, 1995) resulting in an increased synthesis and paracrine release of oxytocin (Item 2, Figure 1). Both exogenous oestrogen and oxytocin have been shown to increase uterine peristaltic activity (Figure 2) (Kunz *et al.*, 1998a). Since peripheral oestradiol is not elevated in women with endometriosis compared with that of controls (Leyendecker *et al.*, 1996), it is reasonable to assume that hyperperistalsis in women with endometriosis (Item 5, Figure 1) is induced by the increased tissue concentration of oestrogen in the eutopic endometrium (Takahashi *et al.*, 1989), mediated by increased endometrial

oxytocin. Hyperperistalsis may stimulate in a vicious circle the inflammatory response system (Item 1, Figure 1) by constant trauma. In this respect, in infertile women with mostly mild and moderate endometriosis, hyperperistalsis with constant trauma at the fundo-cornual raphe of the subendometrial myometrium (Noe *et al.*, 1998) may even constitute the primary event.

Endometrial oestrogen may also stimulate the production of growth factors (Item 3, Figure 1) within the endometrial stroma that results in processes of proliferation at the endometrio-myometrial junction (Fujii *et al.*, 1989) and in the expansion of the endometrium with a possible infiltration into the stratum vasculare of the myometrium (Item 4, Figure



**Figure 2.** The frequency of uterine peristaltic contractions during the follicular phase of the menstrual cycle in healthy women; in those with endometriosis; in those treated with human menopausal gonadotrophin (HMG), which resulted in unphysiologically high concentrations of oestradiol in serum; and in normal women treated with an i.v. bolus of oxytocin. The data show that high oestradiol concentrations and bolus injections of oxytocin, respectively, simulate the significantly increased uterine peristalsis in patients with endometriosis in comparison with that in healthy women. Values are mean  $\pm$  SEM (modified from Leyendecker *et al.*, 1996 and Kunz *et al.*, 1998a). VSUP = vaginal sonography of uterine peristalsis.

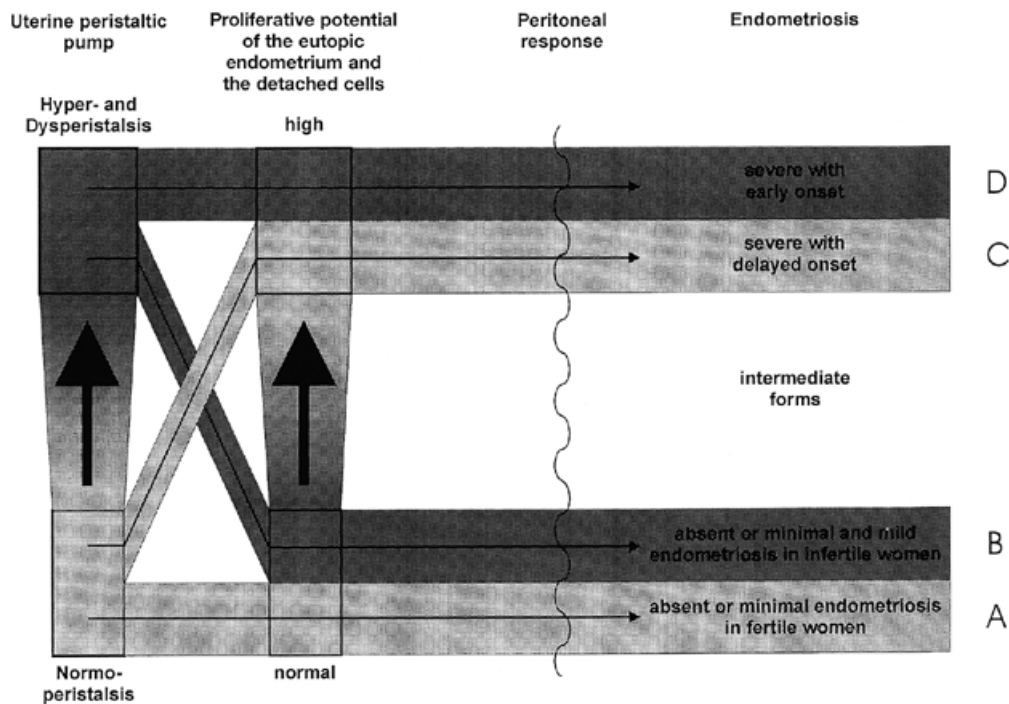
1) (Kunz, Noe, Herbertz, Mall, Leyendecker, unpublished). Both the increased local release of oxytocin and the structural changes on the level of the myometrium result in dysperistalsis (Item 5, Figure 1), impeded sperm transport (Item 6) and functional uterine sterility (Item 7) (Leyendecker *et al.*, 1996). Prior to the disclosure of impeded sperm transport as a uterine dysfunction and an important disturbance in the process of reproduction, sterility and subfertility associated with mild and moderate endometriosis were considered as idiopathic.

Hyper- and dysperistalsis increase the amount of endometrial tissue transported via the tubes into the peritoneal cavity. This results mostly in mild and moderate endometriosis (Item 8, Figure 1) which is often asymptomatic and therefore usually diagnosed during fertility work-up. Since hyperperistalsis is present already during the early follicular phase (Leyendecker *et al.*, 1996) and also during menstruation (Salamanca and Beltran, 1995), retrograde menstruation may be increased or newly proliferating cells together with stromal elements may be abraded by the increased peristaltic activity and transported into the peritoneal cavity. The process of transtubal transport of endometrial cells and tissue elements is, however, increased during the whole cycle (Bartosik *et al.*, 1986).

As an autologous tissue, for implantation in the peritoneal cavity, eutopic endometrial tissue does not necessarily need

to be severely altered with respect to the potential for implantation and invasion. Otherwise experimental endometriosis in subhuman primates would not be possible (Telinde and Scott, 1950; Sillem *et al.*, 1996). That is why most infertile patients present with low-grade endometriosis as do fertile women who develop endometriosis following a long interval of time after their last pregnancy (Moen, 1991; Moen and Muus, 1991). Thus, in these infertile women, it is not the dissemination of endometrial tissue in the peritoneal cavity that causes dysfunction but rather the impeded sperm transport. That is why treatment focusing on the endometrial lesions is ineffective in treating infertility (Hull *et al.*, 1988; Adamson and Pasta, 1994). We would like to denominate this concept as the 'hyperperistalsis pathway' to endometriosis.

While hyperperistalsis induced by increased local oestrogen concentrations takes advantage of a pre-existing physiological mechanism of the archimetra, the potential for increased proliferation and invasiveness of eutopic endometrial tissue in consequence of chronically elevated tissue oestradiol concentrations most probably requires qualitative changes, presumably genomic (Starzinsky-Powitz *et al.*, 1998), in the tissues involved. Thus, infiltrative endometriosis (Item 12, Figure 1) developing along the 'hyperproliferative pathway' would result from the transtubal transport (Item 11) of eutopic



**Figure 3.** A schematic representation of the two principal pathways in the development of endometriosis. Although both hyperperistalsis and hyperproliferation result from locally increased oestrogenic stimulation, their expression might be different in individual cases. Furthermore, hyperproliferation might differentially evolve in individual endometriotic implants in the same patient.

endometrium with an increased potential for proliferative and infiltrative growth (Item 10). At the site of implantation, inflammatory processes with the involvement of cytokines and growth factors such as vascular endothelial growth factor might promote the local disease and result eventually in adhesions (Item 13) and tubo-ovarian sterility (Item 14). Furthermore, an increased potential to express P450 aromatase (Noble *et al.*, 1997) and an increased potential for infiltrative growth (Gaetje *et al.*, 1995) may be acquired at the level of the endometriotic lesions in response to cytokines and growth factors that are abundant in peritoneal fluid of patients with endometriosis.

In addition, and also on the level of the endometriotic implants, elevated oestrogen levels stimulate the autocrine/paracrine OT/OTR/PGE2 system, which may further stimulate the expression of the P450 aromatase. In endometriosis-derived stromal cells, the stimulation of the aromatase expression by PGE2 is more pronounced than in the respective eutopic endometrium (Noble *et al.*, 1997). In endometriosis developing predominantly along the 'hyperproliferative pathway', the symptoms arising from pelvic endometriosis characterize the clinical appearance of the disease in addition to the subfertility. A schematic representation of the two principal pathways in the development of endometriosis and their clinical consequences is given in Figure 3.

Adenomyosis (Item 15, Figure 1) has been termed a junctional zone disease (Brosens *et al.*, 1995, 1998). Adenomyosis shares, according to this model, some important pathophysiological steps with endometriosis and appears to be, indeed, a special variant of endometriosis. With stroma and epithelium, there is a proliferation and infiltration of elements of the archimetra into the outer myometrial layers. There is circumstantial evidence that local oestrogen concentrations are elevated (Takahashi *et al.*, 1989) and that cytochrome P450 aromatase is expressed (Kitawaki *et al.*, 1997). Not infrequently, adenomyosis is associated with endometriosis and, if adenomyotic nodules penetrate the uterine serosa, massive pelvic endometriosis may ensue (Jones and Jones, 1981). The profile of the patients, however, is often different from that of patients with endometriosis (Parazzini *et al.*, 1996), which may hint at a different starting point in the pathophysiology of endometriosis and adenomyosis respectively, or may indicate that similar causal events become effective at different stages during reproductive life. While, according to circumstantial evidence on the basis of endometrial ablation (McLucas, 1994; Yuen, 1995; McCausland and McCausland, 1996) adenomyosis and possibly also endometriosis of parous and primarily fertile women may result from trauma and overreactive repair of the archimetra following pregnancy and delivery, endometriosis in primarily infertile women



may result from hyperreactive repair in response to constant trauma of the archimetra by chronic hyperperistalsis.

Ovarian endometriomas are believed to result from the invagination of primarily superficial lesions and recto-vaginal endometriosis from deep infiltrative endometriosis in the cul-de-sac. Recently, it was suggested on the basis of histological characteristics that, while peritoneal endometriosis would result from transtubal transplantation, solitary ovarian endometriomas may arise from metaplasia within ovarian inclusion cysts and recto-vaginal endometriosis may develop from Müllerian remnants (Nisolle and Donnez, 1997). Within the context of our model, this would mean that, in those cases with solely ovarian endometriomas or solely recto-vaginal endometriosis, certain characteristics of a primary involvement of the archimetra would be lacking, including functional and structural alterations such as expression and hyperexpression of P450 aromatase (Noble *et al.*, 1996; 1997) and MCP-1 (Jolicœur *et al.*, 1998), hyper- and dysperistalsis (Leyendecker *et al.*, 1996), increased intrauterine pressure (Mäkäräinen *et al.*, 1988; Bulletti *et al.*, 1997) and infiltrative expansion of the endometrium (Kunz, Noe, Herbertz, Leyendecker, unpublished).

In conclusion, evidence is provided in this paper that endometriosis constitutes primarily a disease of the archimetra. The view is advanced that this disease takes advantage of pre-existing physiological mechanisms such as inflammatory defence, normal proliferative processes in all layers of the archimetra and uterine peristalsis. Consequently, pre-existing biochemical regulatory mechanisms of the archimetra are utilized. Increased tissue concentrations of oestradiol as a consequence of pathologically expressed P450 aromatase appear to be a central event in the pathogenesis of the disease. Whether a hyperactivated inflammatory response or a hyperactivated OT/OTR system within in the epithelium is the primary event of which the triggers are unknown, or whether several starting mechanisms exist, remains to be elucidated. Since endometriosis (and adenomyosis) is a very common disease, its cause or causes, may be unspectacular and closely related to the process of reproduction. Trauma, such as arising from uterine peristalsis or hyperperistalsis as well as pregnancy and delivery, followed by tissue specific hyperreactive inflammatory response and repair involving specific biochemical mechanisms of the archimetra as delineated above, may be considered to be the major events in the development of the disease. The presented model is able to explain the hitherto enigmatic infertility in mild-to-moderate endometriosis.

## References

- Adamson, G.D. and Pasta, D.J. (1994) Surgical treatment of endometriosis-associated infertility: analysis compared with survival analysis. *Am. J. Obstet. Gynecol.*, **171**, 1488–1505.
- Aplin, J.D. (1989) Cellular biochemistry of the endometrium. In Wynn, R.M. and Jollie, W.P. (eds), *Biology of the Uterus*. Plenum Medical Book Company, New York, pp. 89–130.
- Arici, A., Oral, E., Attar, E. *et al.* (1997) Monocyte chemotactic protein-1 concentration in peritoneal fluid of women with endometriosis and its modulation of expression in mesothelial cells. *Fertil. Steril.*, **67**, 1065–1072.
- Asselin, E., Goff, A.K., Bergeron, H. and Fortier, M.A. (1996) Influence of sex steroids on the production of prostaglandins F2 alpha and E2 and response to oxytocin in cultured epithelial and stromal cells of the bovine endometrium. *Biol. Reprod.*, **54**, 371–379.
- Bartosik, D., Jakobs, S.L. and Kelly, L.J. (1986) Endometrial tissue in peritoneal fluid. *Fertil. Steril.*, **46**, 796.
- Bergqvist, A., Brunkwall, J. and Ploman, F. (1997) Concentration of prostaglandin F2a in follicular fluid from women with endometriosis. *Hum. Reprod.*, **12**, 1789–1793.
- Bois, F.Y. and Eskanazi, B. (1994) Possible risk of endometriosis for Seveso, Italy, residents, an assessment of exposure to oxytocin. *Environ. Health Perspect.*, **102**, 476–477.
- Braun, D.P., Muriana, A., Gebel, H. *et al.* (1994) Monocyte mediated enhancement of endometrial cell proliferation in women with endometriosis. *Fertil. Steril.*, **61**, 78–84.
- Brosens, J.J., de Souza, N.M. and Barke, F.G. (1995) Uterine junctional zone: function and disease. *Lancet*, **346**, 558–560.
- Brosens, J.J., Barker, F.G. and de Souza, N.M. (1998) Myometrial zonal differentiation and uterine junctional zone hyperplasia in the non-pregnant uterus. *Hum. Reprod. Update*, **4**, 496–502.
- Brown, H.K., Stoll, B.S., Nicosia, S.V. *et al.* (1991) Uterine junctional zone: Correlation between histological findings and MR imaging. *Radiology*, **178**, 409–413.
- Bulletti, C., Rossi, S., de Ziegler, D. *et al.* (1997) The uterine contractility in endometriosis. International Meeting on Infertility and Assisted Reproductive Technology, Porto Cervo, Italy, June 11–14, 1997. Abstract Book pp. 129.
- Carson, D.D., DeSouza, M.M., Kardon, R. *et al.* (1998) Mucin expression and function in the female reproductive tract. *Hum. Reprod.*, **13**, Suppl.
- Danet-Desnoyers, G., Wetzels, C. and Thatcher, W.W. (1994) Natural and recombinant interferon-tau regulate basal and oxytocin-induced secretion of prostaglandins F2alpha and E2 by epithelial cells and stromal cells in the endometrium. *Reprod. Fertil. Dev.*, **6**, 193–202.
- De Vries, K., Lyons, E.A., Ballard, G. *et al.* (1990) Contractions of the inner third of the myometrium. *Am. J. Obstet. Gynaecol.*, **162**, 679–682.
- Einer-Jensen, N. (1988) Countercurrent transfer in the ovarian pedicle and its physiological implications. *Oxford. Reviews*, **10**, 348–381.
- Eskenazi, B. and Kimmel, G. (1995) Workshop on perinatal exposure to dioxin-like compounds. II. Reproductive effects. *Environ. Health Perspect.*, **103**, (suppl. 2), 143–145.
- Faundes, A., Montes de Oca, V., Brache, V. and Alvarez-Sanchez, F. (1981) Sperm migration at different stages of the menstrual cycle. *Int. J. Gynaecol. Obstet.*, **19**, 361–366.
- Fleischer, A., Kalemeris, G.C. and Entmann, S.S. (1986) Sonographic depiction of the endometrium of the endometrium during normal cycles. *Ultrasound Med. Biol.*, **12**, 271–277.
- Fuchs, A.R., Ivell, R., Fields, P.A. *et al.* (1996) Oxytocin receptors in bovine cervix: distribution and gene expression during the estrous cycle. *Biol. Reprod.*, **54**, 700–708.
- Fujii, S., Konishi, I. and Mori, T. (1989) Smooth muscle differentiation at endometrio-myometrial junction. An ultrastructural study. *Virch. Archiv. A. Pathol. Anat.*, **414**, 105–112.
- Gaetje, R., Kotzian, S., Herrmann, G. *et al.* (1995) Invasiveness of endometriotic cells *in vitro*. *Lancet*, **346**, 1463–1464.

- Gipson, I.K., Ho, S.B., Spur-Michaud, S.J. *et al.* (1997) Mucin genes express by human female reproductive tract epithelia. *Biol. Reprod.*, **56**, 999–1011.
- Gross, T.S., Thatcher, W.W., Hansen, P.J. and Lacroix, M.C. (1988) Prostaglandin secretion by perfused bovine endometrium: secretion towards the myometrial and luminal sides at day 17 post-estrus as altered by pregnancy. *Prostaglandins*, **35**, 343–357.
- Guidice, L.C. and Ferenzy, A. (1996) The endometrial cycle. In Adashi E.Y., Rock J.A. and Rosenwaks Z. (eds), *Reproductive Endocrinology, Surgery and Technology*. Lippincott Raven, Philadelphia, PA, pp. 271–300.
- Halme, J., White, C., Kauma, S. *et al.* (1988) Peritoneal macrophages from patients with endometriosis release growth factor activity *in vitro*. *J. Clin. Endocrinol. Metab.*, **66**, 1044–1049.
- Harper, M.J.K. (1994) Gamete and zygote transport. In Knobil, E. and Neill, J.D. (eds), *The Physiology of Reproduction*. Raven Press, New York, pp. 123–187.
- Hey, N.A., Graham, R.A., Seif, M.W. and Aplin, J.D. (1994) The polymorphic epithelial mucin MUC1 in human endometrium is regulated with maximal expression in the implantation phase. *J. Clin. Endocrinol. Metab.*, **78**, 337–342.
- Hricak, H., Alpers, C., Crooks, L.E. and Sheldon, P.E. (1983) Magnetic resonance imaging of the female pelvis: Initial experience. *Am. J. Rad.*, **141**, 119–1128.
- Hull, M.E., Moghissi, K.S., Magyar, D.F. and Hayes, M.F. (1986) Comparison of different treatment modalities of endometriosis in infertile women. *Fertil. Steril.*, **47**, 40.
- Isaacson, K., Galman, M., Coutifaris, C. and Lyttle, C. (1990) Endometrial synthesis and secretion of complement component-3 by patients with and without endometriosis. *Fertil. Steril.*, **53**, 836–841.
- Jolicoeu, C., Boutouil, M., Drouin, R. *et al.* (1998) Increased expression of monocyte chemoattractant protein-1 in the endometrium of women with endometriosis. *Am. J. Pathol.*, **152**, 125–133.
- Jansen, R.P.S. (1980) Cyclic changes in the human fallopian tube isthmus and their functional importance. *Am. J. Obstet. Gynaecol.*, **136**, 292–308.
- Karck, U., Reister, F., Schäfer, W. *et al.* (1996) PGE2 and PGF2alpha release by human peritoneal macrophages in endometriosis. *Prostaglandins*, **51**, 49–60.
- Kennedy, S. (1997) Is there a genetic basis to endometriosis? *Semin. Reprod. Endocrinol.*, **15**, 309–318.
- Kim, J.J. and Fortier, M.A. (1995) Cell type specificity and protein kinase C dependency on the stimulation of prostaglandin E2 and prostaglandin F2 alpha production by oxytocin and platelet-activating factor in bovine endometrial cells. *J. Reprod. Fertil.*, **103**, 239–247.
- King, A., Burrows, T., Verma, S. *et al.* (1998) Human uterine lymphocytes. *Hum. Reprod. Update*, **4**, 480–485.
- Kitawaki, J., Noguchi, T., Amatsu, T. *et al.* (1997) Expression of aromatase cytochrome P450 protein and messenger ribonucleic acid in human endometriotic and adenomyotic tissues but not in normal endometrium. *Biol. Reprod.*, **57**, 514–519.
- Koninckx, P.R., Braet, P., Kennedy, S.H. and Barlow, D.H. (1994) Dioxin pollution and endometriosis in Belgium. *Hum. Reprod.*, **9**, 1001–1002.
- Kruitwagen, R.F.P.M., Poels, L.G., Willemsen, W.N.P. *et al.* (1991) Retrograde seeding of endometrial cells by uterine-tubal flushing. *Fertil. Steril.*, **56**, 414–420.
- Kunz, G., Beil, D., Deininger, H., Wildt, L. and Leyendecker, G. (1996) The dynamics of rapid sperm transport through the female genital tract. Evidence from vaginal sonography of uterine peristalsis (VSUP) and hysterosalpingoscintigraphy (HSSG). *Hum. Reprod.*, **11**, 627–632.
- Kunz, G., Beil, D., Deininger, H. *et al.* (1997) The uterine peristaltic pump. Normal and impeded sperm transport within the female genital tract. (In Ivell, R. and Holstein, A.-F. (eds), *The Fate of the Male Germ Cell*. Plenum Press, New York) *Advances Exp. Med. Biol.*, **424**, 267–277.
- Kunz, G., Noe, M., Herbertz, M. and Leyendecker, G. (1998a) Uterine peristalsis during the follicular phase of the menstrual cycle. Effects of oestrogen, antioestrogen and oxytocin. *Hum. Reprod. Update*, **4**, 647–654.
- Kunz, G., Herbertz, M., Noe, M. and Leyendecker, G. (1998b) Sonographic evidence for the involvement of the utero-ovarian counter-current system in the ovarian control of directed sperm transport. *Hum. Reprod. Update*, **4**, 667–672.
- Kunz, G., Beil, D. and Leyendecker, G. (1998c) Cervical mucus does not act a barrier during the luteal phase of the menstrual cycle. Evidence from hysterosalpingoscintigraphy (HSSG). *Hum. Reprod.*, **13**, (Abstract Bk. 1), 341–342.
- Kunz, G., Noe, M. and Leyendecker, G. (1998d) The stratum subvasculare of the myometrium is expanded in patients with endometriosis. *Hum. Reprod.*, **13**, (Abstract Bk. 1) p 254.
- Lee, J.K.T., Gersell, D.J., Balfe, D.M. *et al.* (1985) The uterus: *in vitro* MR - anatomic correlation of normal and abnormal specimens. *Radiology*, **156**, 175–179.
- Leiva, M.C., Hasty, L.A. and Lyttle, C.R. (1994) Inflammatory changes of the endometrium in patients with minimal-to-moderate endometriosis. *Fertil. Steril.*, **62**, 967–972.
- Lessey, B.A., Castelbaum, A.J., Sawin, S.W. *et al.* (1994) Aberrant integrin expression in the endometrium of women with endometriosis. *J. Clin. Endocrinol. Metab.*, **79**, 643–649.
- Leyendecker, G., Kunz, G., Wildt, L. *et al.* (1996) Uterine hyperperistalsis and dysperistalsis as dysfunctions of the mechanism of rapid sperm transport in patients with endometriosis and infertility. *Hum. Reprod.*, **11**, 1542–1551.
- Loke, Y.W. and King, A. (1996) Immunology of human implantation: an evolutionary perspective. *Hum. Reprod.*, **11**, 283–286.
- Lyons, E.A., Taylor, P.J., Zheng, X.H. *et al.* (1991) Characterisation of subendometrial myometrial contractions throughout the menstrual cycle in normal fertile women. *Fertil. Steril.*, **55**, 771–775.
- Mäkäräinen, L. (1988) Uterine contractions in endometriosis: effects of operative and danazol treatment. *J. Obstet. Gynecol.*, **9**, 134–138.
- Malinak, L.R., Buttram, V.C., Elias, S. and Simpson, J.L. (1980) Heritable aspects of endometriosis II. Clinical characteristics of familial endometriosis. *Am. J. Obstet. Gynaecol.*, **127**, 332.
- Mayani, A., Barel, S., Soback, S. and Almagor, M. (1997) Dioxin concentrations in women with endometriosis. *Hum. Reprod.*, **12**, 373–375.
- McBean, J.H. and Brumsted, J.R. (1993) *In vitro* secretion by endometrium from women with advanced endometriosis. *Fertil. Steril.*, **59**, 89–92.
- McBean, J.H., Gibson, M. and Brumsted, J.R. (1996) The association of intrauterine filling defects on hysterosalpingogram with endometriosis. *Fertil. Steril.*, **66**, 522–526.
- McLaren, J., Prentice, A., Charnock-Jones, D.S. *et al.* (1996) Vascular endothelial growth factor is produced by peritoneal fluid macrophages in endometriosis and is regulated by ovarian steroids. *J. Clin. Invest.*, **98**, 482–489.
- Mizumoto, Y., Furuya, K., Makimura, N. *et al.* (1995) Gene expression of oxytocin receptor in human eutopic endometrial tissues. *Adv. Exp. Med. Biol.*, **395**, 491–493.
- Moen, M.H. (1991) Is a long period without childbirth a risk factor for developing endometriosis? *Hum. Reprod.*, **6**, 1404.
- Moen, M.H. and Muus, K.M. (1991) Endometriosis in pregnant and non-pregnant women at tubal sterilisation. *Hum. Reprod.*, **6**, 699.
- Nisolle, M. and Donnez, M. (1997) Peritoneal endometriosis, ovarian endometriosis, and adenomyotic nodules of the rectovaginal septum are three different entities. *Fertil. Steril.*, **68**, 585–596.
- Noble, L.S., Simpson, E.R., Johns, A. and Bulun, S.E. (1996) Aromatase expression in endometriosis. *J. Clin. Endocrinol. Metab.*, **81**, 174–179.
- Noble, L.S., Takayama, K., Zeitoun, K.M. *et al.* (1997) Prostaglandin E2 stimulates aromatase expression in endometriosis-derived stromal cells. *J. Clin. Endocrinol. Metab.*, **82**, 600–606.
- Noe, M., Kunz, G., Herbertz, M. *et al.* (1999) The cyclic pattern of the immunocytochemical expression of oestrogen and progesterone receptors in human myometrial and endometrial layers: Characterisation of the endometrial-subendometrial unit. *Hum. Reprod.*, **14**, in press.

- Olive, D.L., Montoya, I., Riehl, M. and Schenken, R.S. (1991) Macrophage-conditioned media enhance endometrial stromal cell proliferation *in vitro*. *Am. J. Obstet. Gynecol.*, **164**, 953–958.
- Ota, H., Igarashi, S., Hayakawa, M. *et al.* (1996) Effect of danazol on the immunocompetent cells in the eutopic endometrium in patients with endometriosis: a multicenter cooperative study. *Fertil. Steril.*, **65**, 545–551.
- Ota, H., Igarashi, S., Hatazawa, J. and Tanaka, T. (1997) Distribution of heat shock proteins in eutopic and ectopic endometrium in endometriosis and adenomyosis. *Fertil. Steril.*, **68**, 23–28.
- Parazzini, F., Vercellini, P., Panazza, S. *et al.* (1997) Risk factors for adenomyosis. *Hum. Reprod.*, **12**, 1275–1279.
- Prefontaine, M., Shih, C., Pan, C.C. and Bhavnani, B.R. (1990) Applicability of the product isolation and the radiometric aromatase assays for the measurement of low levels of aromatase: lack of aromatase activity in the human endometrium. *J. Endocrinol.*, **127**, 539–551.
- Rana, N., Braun, D.P., House, R. *et al.* (1996) Basal and stimulated secretion of cytokines by peritoneal macrophages in women with endometriosis. *Fertil. Steril.*, **65**, 925–930.
- Rier, S.E., Martin, D.C., Bowman, R.E. *et al.* (1993) Endometriosis in rhesus monkeys (*Macaca mulatta*) following chronic exposure to 2,3,7,8-tetrachlorodibenzo-p-dioxin. *Fundam. Appl. Toxicol.*, **21**, 433–441.
- Roberts, D.K., Walker, N.J. and Lavia, L.A. (1988) Ultrastructural evidence of stromal/epithelial interactions in the human endometrial cycle. *Am. J. Obstet. Gynecol.*, **158**, 854–861.
- Sampson, J.A., (1927) Peritoneal endometriosis due to the menstrual dissemination of endometrial tissue into the peritoneal cavity. *Am. J. Obstet. Gynaecol.*, **14**, 422–429.
- Salamanca, A. and Beltran, E. (1995) Subendometrial contractility in menstrual phase visualised by transvaginal sonography in patients with endometriosis. *Fertil. Steril.*, **64**, 193–195.
- Scoutt, L.M., Flynn, S.D., Luthringer, D.J. *et al.* (1991) Junctional zone of the uterus: Correlation of MR imaging and histologic examination of hysterectomy specimens. *Radiology*, **179**, 403–407.
- Shemesh, M., Dombrowski, L., Gurevich, M. *et al.* (1997) Regulation of bovine cervical secretion of prostaglandins and synthesis of cyclooxygenase by oxytocin. *Reprod. Fertil. Dev.*, **9**, 525–530.
- Simpson, J.L., Elias, S., Melinak, L.R. and Buttram, V.C. (1980) Heritable aspects of endometriosis: I genetic studies. *Am. J. Obstet. Gynaecol.*, **137**, 327.
- Sillem, M., Hahn U., Coddington, C.C. *et al.* (1996) Ectopic growth of endometrium depends on its structural integrity and proteolytic activity in the cynomolgus monkey (*Macaca fascicularis*) model of endometriosis. *Fertil. Steril.*, **66**, 468–473.
- Sillem, M., Prifti, S., Monga, B. *et al.* (1997) Soluble urokinase-type plasminogen activator receptor is over-expressed in uterine endometrium from women with endometriosis. *Mol. Hum. Reprod.*, **3**, 1101–1105.
- Starzinski-Powitz, A., Gaetje, R., Kotzian, S. *et al.* (1998) Tracing cellular and molecular mechanisms involved in endometriosis. *Hum. Reprod. Update*, **4**, 723–728.
- Surveyor, G.A., Gendler, S.J., Pemberton, L. *et al.* (1995) Expression and steroid hormonal control of MUC-1 in the mouse uterus. *Endocrinology*, **136**, 3639–3647.
- Takahashi, K., Nagata, H. and Kitao, M. (1989) Clinical usefulness of determination of estradiol levels in the menstrual blood for patients with endometriosis. *Acta Obstet. Gynecol. Jpn*, **41**, 1849–1850.
- Takahashi, K., Nagata, H., Abu Musa, A. *et al.* (1990) Clinical usefulness of CA 125 levels in the menstrual discharge in patients with endometriosis. *Fertil. Steril.*, **54**, 360–362.
- Takemura, M., Nomura, S., Kimura T. *et al.* (1993) Expression and localisation of oxytocin receptor gene in human uterine endometrium in relation to the menstrual cycle. *Endocrinology*, **132**, 1830–1835.
- Telinde, R.W. and Scott, R.B. (1950) Experimental endometriosis. *Am. J. Obstet. Gynecol.*, **60**, p. 1173.
- Tsai, M.L., Webb, R.C. and Loch-Carusio, R. (1997) Increase in oxytocin-induced oscillatory contractions by 4-hydrated-2',4',6'-trichlorobiphenyl is estrogen receptor mediated. *Biol. Reprod.*, **56**, 341–347.
- Tsang, J.F., Ryan, I.P. and Milam, T.D. (1996) Interleukin-6 secretion *in vitro* is upregulated in ectopic and eutopic endometrial stromal cells from women with endometriosis. *J. Clin. Endocrinol. Metab.*, **81**, 1118–1122.
- Wetzstein, R. (1965) Der Uterusmuskel: Morphologie. *Arch. Gynecol.*, **202**, 1–13.
- Werth, R. and Grusdew, W. (1898) Untersuchungen über die Entwicklung und Morphologie der menschlichen Uterusmuskulatur. *Arch. Gynäkol.*, **55**, 325–409.
- Wildt, L., Kissler, S., Licht, P. and Becker, W. (1998) Sperm transport in the human female genital tract and its modulation by oxytocin as assessed by hysterosalpingoscintigraphy, hysteronography, electrohystero-graphy and Doppler sonography *Hum. Reprod. Update.*, **4**, 655–666.
- Wingfield, M., Macpherson, A., Healy, D. L. and Rogers P.A.W. (1995) Cell proliferation is increased in the endometrium of women with endometriosis. *Fertil. Steril.*, **64**, 340–346.
- Xu, L., Wu, Q. and Wang, B. (1995) Antibacterial components of rat uterus. *Hua Hsi I Ko Ta Hsueh Hsueh Pao*, **26**, 261–265.
- Yamamoto, T., Noguchi, T., Tamura, T. *et al.* (1993) Evidence for oestrogen synthesis in adenomyotic tissues. *Am. J. Obstet. Gynaecol.*, **169**, 734–738.
- Zingg, H.H., Rosen, F., Chu, K. *et al.* (1995) Oxytocin and oxytocin receptor gene expression in the uterus. *Recent Progr. Hormone Res.*, **50**, 255–273.